

Comparative Study of Skeletal Stability between Postoperative Skeletal Intermaxillary Fixation and No Skeletal Fixation after Bilateral Sagittal Split Ramus Osteotomy: an 18 Months Retrospective Study

Jens Hartlev^{1,2}, Erik Godtfredsen³, Niels Trolle Andersen⁴, Thomas Jensen¹

¹Department of Oral and Maxillofacial Surgery, Aalborg University Hospital, Aalborg, Denmark.

²Department of Oral and Maxillofacial Surgery, Aarhus University Hospital, Aarhus, Denmark.

³Section of Oral Radiology, School of Dentistry, Health, Aarhus University, Aarhus, Denmark.

⁴Section of Biostatistics, School of Public Health, Health, Aarhus University, Aarhus, Denmark.

Corresponding Author:

Jens Hartlev

Department of Oral and Maxillofacial Surgery, Aarhus University Hospital

Noerrebrogade 44, Bygn 9D, DK-8000 Aarhus C

Denmark

Phone: +4578462927

Fax: +4578464442

E-mail: jenhar@rm.dk

ABSTRACT

Objectives: The purpose of the present study was to evaluate skeletal stability after mandibular advancement with bilateral sagittal split osteotomy.

Material and Methods: Twenty-six patients underwent single-jaw bilateral sagittal split osteotomy (BSSO) to correct skeletal Class II malocclusion. One group (n = 13) were treated postoperatively with skeletal elastic intermaxillary fixation (IMF) while the other group (n = 13) were treated without skeletal elastic IMF.

Results: The mean advancement at B-point and Pog in the skeletal elastic IMF group was 6.44 mm and 7.22 mm, respectively. Relapse at follow-up at B-point was -0.74 mm and -0.29 mm at Pog. The mean advancement at B-point and Pog in the no skeletal elastic IMF group was 6.30 mm and 6.45 mm, respectively. Relapse at follow-up at B-point was -0.97 mm and -0.86 mm at Pog. There was no statistical significant ($P > 0.05$) difference between the skeletal IMF group and the no skeletal group regarding advancement nor relapse at B-point or Pog.

Conclusions: Bilateral sagittal split osteotomy is characterized as a stable treatment to correct Class II malocclusion. This study demonstrated no difference of relapse between the skeletal intermaxillary fixation group and the no skeletal intermaxillary fixation group. Because of selection-bias and the reduced number of patients it still remains inconclusive whether to recommend skeletal intermaxillary fixation or not in the prevention of relapse after mandibular advancement.

Keywords: mandibular advancement; maxillomandibular fixation; orthognatic surgery; relapse; sagittal split ramus osteotomy; skeletal fixation.

Accepted for publication: 27 March 2014

To cite this article:

Hartlev J, Godtfredsen E, Andersen NT, Jensen T. Comparative Study of Skeletal Stability between Postoperative Skeletal Intermaxillary Fixation and No Skeletal Fixation after Bilateral Sagittal Split Ramus Osteotomy: an 18 Months Retrospective Study.

URL: <http://www.ejomr.org/JOMR/archives/2014/1/e2/v5n1e2ht.pdf>

doi: [10.5037/jomr.2014.5102](https://doi.org/10.5037/jomr.2014.5102)

INTRODUCTION

Bilateral sagittal split osteotomy (BSSO) is the most frequent used surgical technique for correcting mandibular deformities and characterized as a highly stable and predictable surgical orthognatic procedure for mandibular advancement [1,2]. A positive correlation between the amount of advancement and relapse has been described in several studies [3-5] and it has been concluded that an advancement of 5 mm or more could predispose to horizontal relapse [6,7].

To minimize horizontal skeletal relapse, BSSO in combination with postoperative skeletal intermaxillary fixation has been advocated [8,9]. However, studies assessing skeletal relapse after BSSO with rigid internal fixation (RIF) and skeletal elastic intermaxillary fixation (IMF) compared to no skeletal elastic IMF has never previously been conducted.

Therefore, the objective of the present study is to estimate the amount of skeletal relapse after single-jaw bilateral sagittal split osteotomy advancement in combination with postoperative skeletal elastic intermaxillary fixation versus no skeletal intermaxillary fixation.

MATERIAL AND METHODS

Patients

From January 2008 to December 2011 a total of 92 consecutively (75 females and 17 males) patients were treated at the Department of Oral and Maxillofacial Surgery, Aalborg University Hospital with BSSO to correct Class II malocclusion. Surgery was performed after the rate of growth was determined to have declined to adult levels. BSSO was performed by 3 senior maxillofacial surgeons and no concomitant surgical procedures were performed.

The inclusion criteria were:

- Mandibular advancement at B-point and/or Pogonion (Pog) over 5 mm in the treatment plan.
- Peroperatively removal of the wafer. This was indicated by a stable occlusion.
- Single-jaw surgery.

Preoperatively the patients were evaluated and the indication for postoperative skeletal elastic IMF was assessed by the surgeon based on the following criteria: 1) preorthodontic open bite, 2) tongue habits, 3) morphological slender condyles estimated radiographically. The skeletal elastic IMF was activated starting one week postoperatively by connecting the 2 wires with 3 elastics and worn 24 hours a day for the following 8 weeks. The patients

were allowed to deactivate the IMF 3 times a day for 1 hour duration. In addition the elastics were used for further 8 weeks nocturnal.

A total of 66 patients were excluded from the study due to:

- Postoperatively maintenance of the wafer (43 patients). This was indicated by an unstable occlusion.
- Mandibular advancement below 5 mm in the treatment plan (17 patients).
- Unavailability to follow-up (4 patients).
- Postoperatively insufficient occlusion on the lateral cephalometric radiographs (2 patients).

Finally 26 patients were included in the study. Thirteen patients were postoperatively treated with skeletal elastic IMF and 13 patients were treated without IMF (Table 1).

Description of procedures

Preoperatively

All patients were seen approximately 14 days preoperatively for the final treatment planning by the responsible surgeon. The treatment plan was conducted by a clinical evaluation of the patient [10], dental cast models, standard lateral cephalometric radiographs (T1/preoperative), and surgical imaging program (Dolphin Imaging & Management Solutions and Patterson Technology, Chatsworth, CA, USA). Derived from these registrations the occlusal splint was fabricated.

Surgical technique

The surgical procedure was conducted in general anaesthesia with nasotracheal intubation, supplemented by local anaesthesia. Initially the intraoperative splint was ligated to the maxillae, before BSSO was performed according to the modified method presented by Hunsuck [11]. The distal segment of the mandible was positioned in the wafer and temporary IMF was initiated by 0.4 mm wires and rubber bands, before the proximal segment was seated by hand.

Table 1. Study population

	Skeletal IMF	No skeletal IMF
Patients (n)	13 (10 F; 3 M)	13 (12 F; 1 M)
Mean age (years)	27 (range 17 - 55)	28 (range 16 - 44)
Follow-up (month)	18 (range 16 - 22)	20 (range 19 - 22)

F = female; M = male; IMF = intermaxillary fixation.

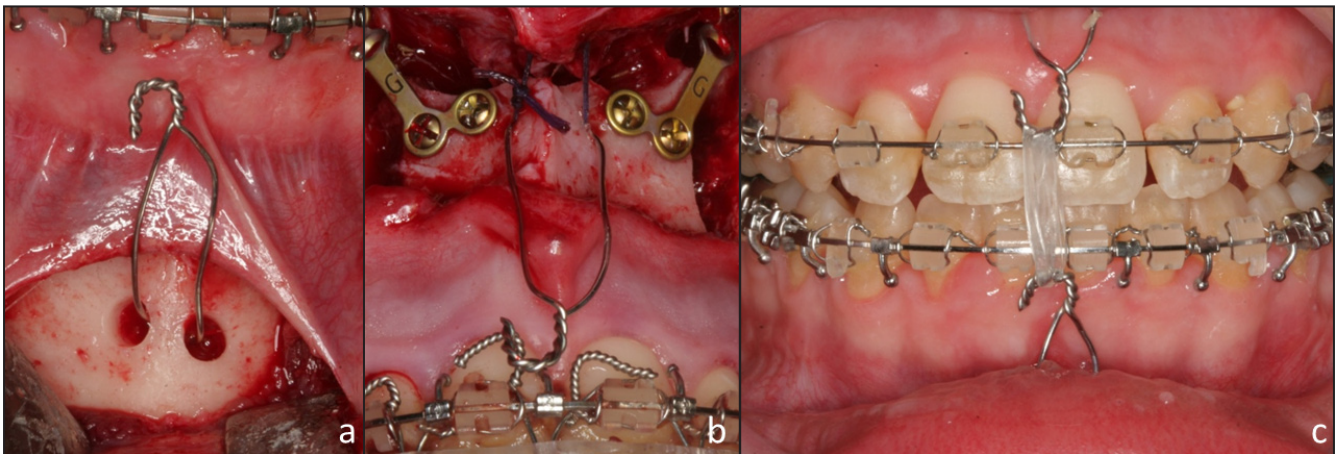


Figure 1. Clinical photo illustrating 0.6 mm skeletal wire placed: a) subcortical in the symphysis region of the mandible, b) in spina nasalis anterior (patient not included in the study), c) activation of the skeletal elastic IMF with 3 rubber bands postoperative.

RIF was performed at the vertical osteotomy line using L-shaped, Y-shaped or 2 straight plates and 5 mm screws (Stryker Corporate, Kalamazoo, Mi, USA). The type of fixation was chosen by an individual preference of the surgeon. At the anterior part of the ramus of the mandible 2-holes plate was used for osteosynthesis. Finally the temporary IMF and the intraoperative wafer were removed.

Preoperatively allocated to postoperative skeletal elastic IMF had a 0.6 mm ligature inserted subcortical in the symphysis region and the spina nasalis anterior by a vestibular approach (Figure 1). The ligature from the upper and lower jaw entered the oral cavity through the previously addresses incisions and were cut and bent hook-shaped at the level of the brackets. Finally the mucosa was sutured with resorbable sutures.

Follow-up regimen

The patients were included in a maintenance program involving 1 day (T2/baseline), 1 week, 3 weeks, 8 weeks, 6 months and 18 months (T3/follow-up) postoperatively follow-up at the Department of Oral and Maxillofacial Surgery, Aalborg, Denmark, respectively. Additionally, the patients were included in an individual maintenance program by their orthodontist.

Outcome measures

The primary outcome measures were:

- Relapse after mandibular advancement, defined as the horizontal change of B-point and Pog from baseline to follow-up.

The secondary outcome measures were:

- Correlation between relapse and amount of advancement.

- Correlation between relapse and vertical facial type. Facial type was categorized in low-angle, average-angle and high-angle [12].

Standard lateral cephalometric radiographs were obtained 14 days preoperatively (T1), immediately postoperatively (T2) (Figure 2), and 18 months (T3) after surgery. Tracing of the digitized radiograph was performed on a personal computer (Por-DiosW, Institute of Orthodontic Computer Science, Middelfart, Denmark) [13], by one calibrated examiner (JH). The correction of magnification was based upon the known distance of the ruler. Magnification, brightness, contrast, and gamma adjustment were used for image enhancement.

An XY-coordinate system was created on the radiograph using the cephalometric Sella-Nasion-line (SN-line) rotated down 7° anteriorly [14,15] as the x axis, and a vertical plane perpendicular to it through sella as the y axis, so that changes in landmark locations were registered as x, y coordinates.

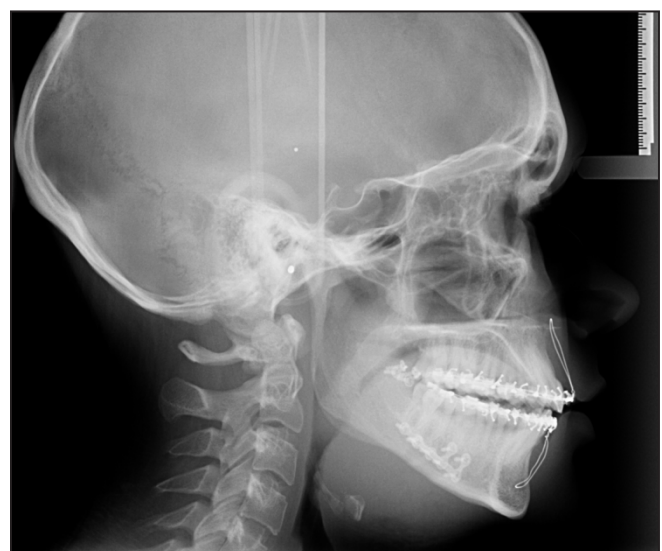

Figure 2. Lateral cephalometric radiograph illustrating skeletal IMF.

Furthermore B-point, Pog, gonion (Go), gnathion (Gn) were also registered. Mandibular plane angle (MP-angle) was defined as the angle between the SN-line and the Gonion-Gnathion-line (Mandibular plane) [12].

Statistical analysis

Data management and analysis including calculation of descriptive statistics were performed using Excel (Microsoft, Redmond, WA, USA) and Stata (StataCorp, College Station, Texas, USA). The results were reported by proportions (%), mean, and 95% confidens interval (95% CI). Correlations between measurements were evaluated with Spearman rank correlation and analysis of variance was performed evaluating difference between the groups and the vertical facial types.

RESULTS

Skeletal IMF

The mean advancement at B-point and Pog was 6.44 mm and 7.22 mm, respectively (Table 2). Relapse at follow-up at B-point was -0.74 mm and -0.29 mm at Pog. There was no correlation between the amount of advancement and the amount of relapse at B-point ($\rho = 0.29$, $P = 0.34$) nor Pog ($\rho = 0.38$, $P = 0.2$) (Figure 3 and 4).

No skeletal IMF

The mean advancement at B-point and Pog was

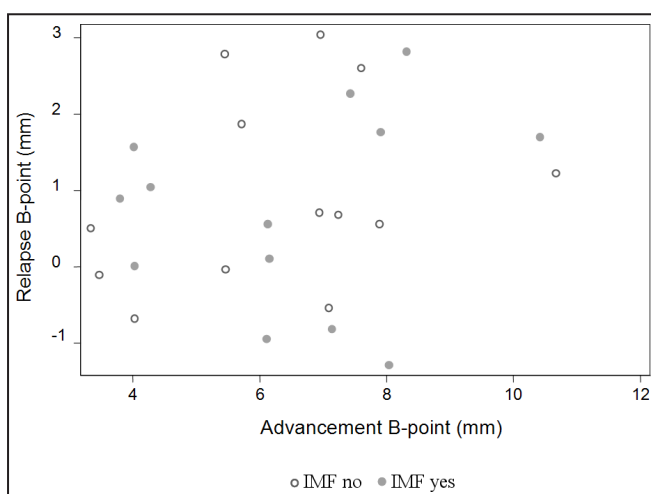


Figure 3. A scatter plot of the correlation between the amount of advancement and relapse at B-point in the skeletal IMF group and in the no skeletal IMF group.

Table 2. Advancement and relapse (mm) in the skeletal and in the no skeletal intermaxillary fixation (IMF) group

	Skeletal IMF	No skeletal IMF	P-value
Advancement B-point Mean (95% CI)	6.44 (5.22 – 7.67)	6.3 (5.07 – 7.52)	0.85
Relapse B-point Mean (95% CI)	-0.74 (-1.52 – -0.03)	-0.97 (-1.73 – -0.21)	0.65
Advancement Pog. Mean (95% CI)	7.22 (5.91 – 8.52)	6.45 (4.88 – 8.01)	0.42
Relapse Pog. Mean (95% CI)	-0.29 (-1,31 – 0.74)	-0.86 (-1.53 – 0.18)	0.32

6.3 mm and 6.45 mm, respectively (Table 2). Relapse at follow-up at B-point was -0.97 mm and -0.86 mm at Pog. There was no correlation between the amount of advancement and the amount of relapse at B-point ($\rho = 0.35$, $P = 0.25$), but at Pog there was ($\rho = 0.58$, $P = 0.04$) (Figure 3 and 4).

There was no statistical significant difference between the skeletal IMF group and the no skeletal group regarding advancement nor relapse at B-point or Pog ($P > 0.05$ for all groups).

Vertical facial type

Seven patients were categorized as short facial types with a relapse of 17% at both B-point and Pog. In the average facial type group, 13 patients were included with a relapse of 13% at B-point and 5% at Pog. The long facial types were characterized with a relapse of 12% at B-point and 7% at Pog (Table 3). The amount of advancement was statistical significant larger in the long facial group than the short and average group (B-point $P = 0.01$, Pog = 0.047). There was no statistical significant difference between the groups regarding relapse ($P > 0.05$ for all groups). No patients were reoperated.

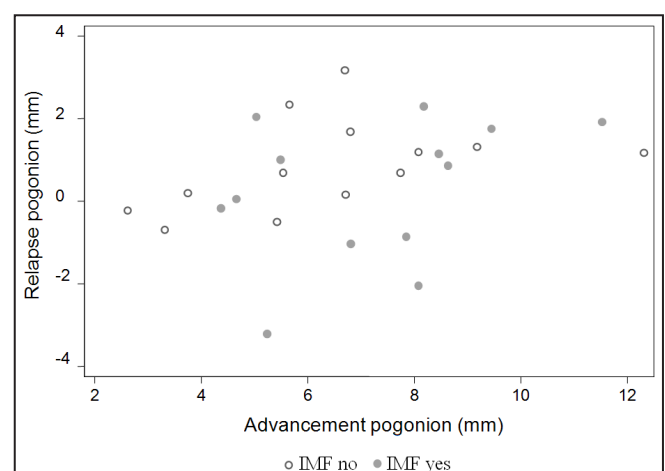


Figure 4. A scatter plot of the correlation between the amount of advancement and relapse at pogonion in the skeletal IMF group and in the no skeletal IMF group.

Table 3. Vertical facial type and amount of relapse (%)

	MP-angle	Patients N	Mean relapse/advancement (mm)	
			B-point	Pog.
Short facial type	< 27°	7	-1.01/6.05 (17%)	-1.06/6.32 (17%)
Average facial type	27 – 36°	13	-0.7/5.63 (13%)	-0.3/6.16 (5%)
Long facial type	≥ 37°	6	-1.02/8.33 (12%)	-0.6/8.88 (7%)

DISCUSSION

The skeletal stability after mandibular advancement with or without anterior skeletal fixation was retrospectively assessed in 26 patients with a mean follow-up of 19 month. Measurements on standard lateral cephalometric radiographs obtained preoperatively, immediately postoperatively, and after a mean follow-up of 19 month demonstrated no statistically difference in skeletal relapse between the 2 treatment modalities. Additionally no statistical significant ($P > 0.05$) correlation between the amount of advancement and relapse was presented in the skeletal IMF-group. On the other hand a significant correlation between the amount of advancement and relapse was revealed in the no skeletal IMF group at Pog.

A total mean relapse of 14% and 8% after 19 month follow-up was seen at B-point and Pog, respectively. The relapse percentage demonstrates relative post-operatively stability approximately equal to previously described long-term (≥ 18 months) results [16]. Skeletal stability must be considered a multifactorial phenomenon where factors as the amount of advancement, the type and material of fixation, low and high mandibular plane angle, skills and experience of the surgeon, and proper management of the proximal segment, soft tissue and muscles may contribute to relapse [7]. Challenging patients with slim condyles and/or tongue habits may also add to a higher frequency of relapse [7]. Finally, the length of follow-up period contributes to the variance of relapse which is described in the literature [17].

This study demonstrated diversity in the correlation between the amount of advancement and relapse. The skeletal IMF group demonstrated no correlation between the amount of advancement and relapse while the no skeletal IMF group at Pog revealed a correlation. Diverse conclusions have been reached addressing this topic previously. A minority of studies proved no correlation between the amount of advancement and relapse [17,18], whereas the majority of studies assessing relapse after BBSO demonstrated a positive correlation between

the amount of advancement and relapse [7,19]. Relapse being a multifactorial phenomenon as previously addressed may explain the difference of correlation between amount of advancement and relapse.

The long facial type group was advanced more than the other

2 groups, but there was no significant difference ($P > 0.05$) between the groups regarding relapse. Long facial types have been described to have a higher amount of relapse after BSSO than short facial types [5,17,20-22]. In the present study this was not validated which can be explained by few patients in the 2 groups (7 and 6 patients).

The present study is characterized by some limitations, including the relative small number of patients and a retrospective study design. The inclusion criterion regarding removal of the wafer preoperatively and thereby reduction of included patients was chosen for the most accurate comparison between the baseline and the follow-up radiographs. The study design is weakened by some degree of selection-bias by grouping the patient by an individual assessment in a skeletal IMF group and in a no skeletal IMF group. Direct comparison with other studies involving mandibular advancement in combination with elastic skeletal IMF was not possible since no other studies regarding this topic, to our knowledge, have been published. Technically the placement of the wire is uncomplicated during surgery, but patients described soreness and discomfort using the skeletal IMF, especially from the wire in the mandible.

CONCLUSIONS

Single-jaw mandibular bilateral sagittal split osteotomy is characterized as a stable and predictable treatment modality to correct Class II occlusion. This study demonstrated no difference of relapse between the skeletal intermaxillary fixation group and the no skeletal intermaxillary fixation group. Because of selection-bias and the reduced number of patients it still remains inconclusive whether to recommend skeletal intermaxillary fixation or not in the prevention of relapse after mandibular advancement. However, postoperative skeletal elastic intermaxillary fixation may minimize relapse in patients with anterior open bite, tongue habits and slim condyles. Further randomized clinical trials with larger study groups are needed before final conclusions can be made regarding this topic.

ACKNOWLEDGMENTS AND DISCLOSURE STATEMENTS

The authors report no conflicts of interests related to this study.

REFERENCES

1. Bailey L', Cevidanes LH, Proffit WR. Stability and predictability of orthognathic surgery. *Am J Orthod Dentofacial Orthop.* 2004 Sep;126(3):273-7. Review. [Medline: [15356484](#)] [PMC free article: [3681098](#)] [doi: [10.1016/j.ajodo.2004.06.003](#)]
2. Proffit WR, Turvey TA, Phillips C. The hierarchy of stability and predictability in orthognathic surgery with rigid fixation: an update and extension. *Head Face Med.* 2007 Apr 30;3:21 [Medline: [17470277](#)] [PMC free article: [1876453](#)] [doi: [10.1186/1746-160X-3-21](#)]
3. Kierl MJ, Nanda RS, Currier GF. A 3-year evaluation of skeletal stability of mandibular advancement with rigid fixation. *J Oral Maxillofac Surg.* 1990 Jun;48(6):587-92. [Medline: [2341939](#)] [doi: [10.1016/S0278-2391\(10\)80471-9](#)]
4. Blomqvist JE, Ahlborg G, Isaksson S, Svartz K. A comparison of skeletal stability after mandibular advancement and use of two rigid internal fixation techniques. *J Oral Maxillofac Surg.* 1997 Jun;55(6):568-74; discussion 574-5. [Medline: [9191638](#)] [doi: [10.1016/S0278-2391\(97\)90486-9](#)]
5. Eggenesperger N, Smolka W, Rahal A, Iizuka T. Skeletal relapse after mandibular advancement and setback in single-jaw surgery. *J Oral Maxillofac Surg.* 2004 Dec;62(12):1486-96. [Medline: [15573348](#)] [doi: [10.1016/j.joms.2004.07.007](#)]
6. Van Sickels JE, Dolce C, Keeling S, Tiner BD, Clark GM, Rugh JD. Technical factors accounting for stability of a bilateral sagittal split osteotomy advancement: wire osteosynthesis versus rigid fixation. *Oral Surg Oral Med Oral Pathol Oral Radiol Endod.* 2000 Jan;89(1):19-23. [Medline: [10630936](#)] [doi: [10.1016/S1079-2104\(00\)80008-6](#)]
7. Joss CU, Vassalli IM. Stability after bilateral sagittal split osteotomy advancement surgery with rigid internal fixation: a systematic review. *J Oral Maxillofac Surg.* 2009 Feb;67(2):301-13. [Medline: [19138603](#)] [doi: [10.1016/j.joms.2008.06.060](#)]
8. Ellis E 3rd, Gallo WJ. Relapse following mandibular advancement with dental plus skeletal maxillomandibular fixation. *J Oral Maxillofac Surg.* 1986 Jul;44(7):509-15. [Medline: [3459835](#)] [doi: [10.1016/S0278-2391\(86\)80090-8](#)]
9. Komori E, Aigase K, Sugisaki M, Tanabe H. Skeletal fixation versus skeletal relapse. *Am J Orthod Dentofacial Orthop.* 1987 Nov;92(5):412-21. [Medline: [3479009](#)] [doi: [10.1016/0889-5406\(87\)90262-9](#)]
10. Arnett GW, Maclaugin RP: The Clinical Examination. In: Arnett and Maclaugins, editors. *Facial and Dental Planning for Orthodontists and Oral Surgeons*, 1. edition. Elsevier Health Sciences; 2003. p. 47-78.
11. Hunsuck EE. A modified intraoral sagittal splitting technic for correction of mandibular prognathism. *J Oral Surg.* 1968 Apr;26(4):250-3. [Medline: [5237786](#)]
12. Karlsen AT. Craniofacial growth differences between low and high MP-SN angle males: a longitudinal study. *Angle Orthod.* 1995;65(5):341-50. [Medline: [8526293](#)]
13. Gotfredsen E, Kragsskov J, Wenzel A. Development of a system for craniofacial analysis from monitor-displayed digital images. *Dentomaxillofac Radiol.* 1999 Mar;28(2):123-6. [Medline: [10522202](#)] [doi: [10.1038/sj.dmfr.4600420](#)]
14. Burstone CJ, James RB, Legan H, Murphy GA, Norton LA. Cephalometrics for orthognathic surgery. *J Oral Surg.* 1978 Apr;36(4):269-77. [Medline: [273073](#)]
15. Rustemeyer J, Martin A. Assessment of Soft Tissue Changes by Cephalometry and Two-Dimensional Photogrammetry in Bilateral Sagittal Split Ramus Osteotomy Cases. *J Oral Maxillofac Res.* 2011 Oct 1;2(3):e2. [Medline: [24421994](#)] [PMC free article: [3886076](#)] [doi: [10.5037/jomr.2011.2302](#)]
16. Kahnberg KE, Kashani H, Owman-Moll P. Sagittal split advancement osteotomy: comparison of the tendency to relapse after two different methods of rigid fixation. *Scand J Plast Reconstr Surg Hand Surg.* 2007;41(4):167-72. [Medline: [17701729](#)] [doi: [10.1080/02844310701270299](#)]
17. Eggenesperger N, Smolka K, Luder J, Iizuka T. Short- and long-term skeletal relapse after mandibular advancement surgery. *Int J Oral Maxillofac Surg.* 2006 Jan;35(1):36-42. [Medline: [16344217](#)] [doi: [10.1016/j.ijom.2005.04.008](#)]
18. Rubens BC, Stoelinga PJ, Blijdorp PA, Schoenaers JH, Politis C. Skeletal stability following sagittal split osteotomy using monocortical miniplate internal fixation. *Int J Oral Maxillofac Surg.* 1988 Dec;17(6):371-6. [Medline: [3145953](#)] [doi: [10.1016/S0901-5027\(88\)80066-3](#)]
19. Joss CU, Thüer UW. Stability of the hard and soft tissue profile after mandibular advancement in sagittal split osteotomies: a longitudinal and long-term follow-up study. *Eur J Orthod.* 2008 Feb;30(1):16-23. [Medline: [17962316](#)] [doi: [10.1093/ejo/cjm080](#)]

20. Mobarak KA, Espeland L, Krogstad O, Lyberg T. Mandibular advancement surgery in high-angle and low-angle class II patients: different long-term skeletal responses. *Am J Orthod Dentofacial Orthop.* 2001 Apr;119(4):368-81. [Medline: [11298310](#)] [doi: [10.1067/mod.2001.110983](#)]
21. Moen K, Wisth PJ, Skaale S, Bøe OE, Tornes K. Dental or skeletal relapse after sagittal split osteotomy advancement surgery? Long-term follow-up. *J Oral Maxillofac Surg.* 2011 Nov;69(11):461-8. [Medline: [21741141](#)] [doi: [10.1016/j.joms.2011.02.086](#)]
22. Aydil B, Özer N, Marşan G. Facial soft tissue changes after maxillary impaction and mandibular advancement in high angle class II cases. *Int J Med Sci.* 2012;9(4):316-21. Epub 2012 Jun 9. [Medline: [22745571](#)] [PMC free article: [3384840](#)] [doi: [10.7150/ijms.4247](#)]

To cite this article:

Hartlev J, Godtfredsen E, Andersen NT, Jensen T. Comparative Study of Skeletal Stability between Postoperative Skeletal Intermaxillary Fixation and No Skeletal Fixation after Bilateral Sagittal Split Ramus Osteotomy: an 18 Months Retrospective Study.

J Oral Maxillofac Res 2014;5(1):e2

URL: <http://www.ejomr.org/JOMR/archives/2014/1/e2/v5n1e2ht.pdf>

doi: [10.5037/jomr.2014.5102](#)

Copyright © Hartlev J, Godtfredsen E, Andersen NT, Jensen T. Published in the JOURNAL OF ORAL & MAXILLOFACIAL RESEARCH (<http://www.ejomr.org>), 1 April 2014.

This is an open-access article, first published in the JOURNAL OF ORAL & MAXILLOFACIAL RESEARCH, distributed under the terms of the [Creative Commons Attribution-Noncommercial-No Derivative Works 3.0 Unported License](#), which permits unrestricted non-commercial use, distribution, and reproduction in any medium, provided the original work and is properly cited. The copyright, license information and link to the original publication on (<http://www.ejomr.org>) must be included.