Skeletal Stability after Large Mandibular Advancement (> 10 mm) with Bilateral Sagittal Split Osteotomy and Skeletal Elastic Intermaxillary Fixation

Kristoffer Schwartz[1,2], Maria Rodrigo-Domingo[3], Thomas Jensen[1]

[1]Department of Oral and Maxillofacial Surgery, Aalborg University Hospital, Aalborg, Denmark.
[2]Department of Oral and Maxillofacial Surgery, Aarhus University Hospital, Aarhus, Denmark.
[3]Department of Clinical Medicine, Aalborg University, Aalborg, Denmark.

Corresponding Author:
Kristoffer Schwartz
Department of Oral and Maxillofacial Surgery
Aarhus University Hospital
Nørrebrogade 44. DK-8000 Aarhus C, Aarhus
Denmark
Phone: + 4524469831
E-mail: kristofferschwartz@hotmail.com

ABSTRACT

Objectives: The aim of the present study was to assess the skeletal stability after large mandibular advancement (> 10 mm) with bilateral sagittal split osteotomy and skeletal elastic intermaxillary fixation and to correlate the skeletal stability with the vertical facial type.
Material and Methods: A total of 33 consecutive patients underwent bimaxillary surgery to correct skeletal Class II malocclusion with a mandibular advancement (> 10 mm) measured at B-point and postoperative skeletal elastic intermaxillary fixation for 16 weeks. Skeletal stability was evaluated using lateral cephalometric radiographs obtained preoperative (T1), 8 weeks postoperatively (T2), and 18 month postoperatively (T3). B-point and pogonion (Pog) was used to measure the skeletal relapse and the mandibular plane angle (MP-angle) was used to determine the vertical facial type.
Results: The mean advancement from T1 to T2 were 11.6 mm and 13.5 mm at B-point and Pog, respectively. The mean skeletal relapse from T2 to T3 was -1.3 mm at B-point and -1.6 mm at Pog. The nineteen patients characterized as long facial types, showed the highest amount of skeletal relapse (-1.5 mm at B-point and -1.9 mm at Pog).
Conclusions: The present study showed a limited amount of skeletal relapse in large mandibular advancement (> 10 mm) with bilateral sagittal split osteotomy and skeletal elastic intermaxillary fixation. Bilateral sagittal split osteotomy in combination with skeletal intermaxillary fixation can therefore be an alternative to distraction osteogenesis in large mandibular advancements.

Keywords: mandibular advancement; maxillomandibular fixation; relapse; sagittal split ramus osteotomy; skeletal fixation.

Accepted for publication: 16 June 2016
To cite this article:
Schwartz K, Rodrigo-Domingo M, Jensen T.
Skeletal Stability after Large Mandibular Advancement (> 10 mm) with Bilateral Sagittal Split Osteotomy and Skeletal Elastic Intermaxillary Fixation
J Oral Maxillofac Res 2016;7(2):e5
URL: http://www.ejomr.org/JOMR/archives/2016/2/e5/v7n2e5.pdf
doi: 10.5037/jomr.2016.7205

INTRODUCTION

Bilateral sagittal split osteotomy (BSSO) is the most frequent used surgical method for correcting mandibular deformities and is known as a highly stable and predictable surgical orthodontic procedure for mandibular advancement [1,2]. The surgical technique was introduced in 1957 by Trauner and Obwegeser [3] and has subsequently been modified by several authors [4,5]. Long-term postsurgical skeletal stability is essential for successful correction of functional and aesthetic abnormalities in mandibular retrognathic patients. Skeletal stability after BSSO advancement with rigid internal fixation has been assessed in a systematic review demonstrating that relapse is a multifactorial phenomenon affected by many different variables [6]. Possible factors for relapse are: the amount of advancement, the type and material of fixation, low and high mandibular plane angle (MP-angle), condylar resorption, control of the proximal segment, soft tissue and muscle tension, remaining growth and remodelling, skills and experience of the surgeon [6]. Moreover, a positive correlation between the amount of advancement and skeletal relapse has been described in several studies [7-9]. BSSO with advancements of up to 7 mm in patients with a low or normal MP-angle are considered stable with minimal long-term postsurgical skeletal relapse [10,11]. Whereas, BSSO with advancements exceeding 7 mm and high MP-angle predispose to postsurgical skeletal relapse [6,9,12].

Distraction osteogenesis has demonstrated a higher postsurgical skeletal stability compared to BSSO in patients with a low or normal MP-angle and large mandibular advancement (> 7 mm) [13]. However, mandibular distraction osteogenesis is associated with a higher incidence of complications and increased patient discomfort compared to BSSO [13,14]. Moreover, a recently published randomized clinical trial demonstrated similar postsurgical skeletal stability with the two treatment modalities in advancements of the mandible of up to 10 mm [15].

To improve the postsurgical skeletal stability and minimize horizontal relapse after large mandibular advancement, BSSO in combination with postoperative skeletal elastic intermaxillary fixation (IMF) has been advocated [16-18]. However, studies assessing postsurgical skeletal relapse after large mandibular advancement with skeletal elastic IMF have never previously been conducted. Therefore, the objective of the present study is to assess the amount of postsurgical skeletal relapse after large mandibular advancement (> 10 mm) combined with postoperative skeletal elastic intermaxillary fixation.

MATERIAL AND METHODS

Patients

From January 2007 to December 2012 a total of 33 consecutive skeletally matured non-syndromal adult patients (20 females and 13 males) with a mean age of 23.2 years (range 16 to 46 years) underwent bimaxillary surgery to correct skeletal Class II malocclusion, with a mandibular advancement > 10 mm measured at B-point. All patients were treated at the Department of Oral and Maxillofacial Surgery, Aalborg University Hospital, Aalborg, Denmark. There was no need for ethical approval. All surgical procedures were performed by 3 senior maxillofacial surgeons and a resident. All patients were planned and had their surgery performed in a sequence whereby the mandible was repositioned and stabilized first, followed by reposition and stabilization of the maxilla [19]. Segmental Le Fort I osteotomy was performed in all the included patients. Indication for postoperative skeletal elastic IMF was assessed by the surgeon based on the following criteria: 1) preorthodontic open bite, 2) large mandibular advancement, 3) tongue habits, 4) morphologically slender condyles estimated radiographically. If the patients fulfilled one of the four criteria, they were assigned for postoperative skeletal elastic IMF.

Description of procedure

Preoperatively

All patients were seen approximately 14 days preoperatively for the final treatment planning by the responsible surgeon. The treatment plan was conducted by a clinical evaluation of the patient [20], dental casts models, standard cephalometric lateral radiographs (T1/preoperative), and a surgical imaging program (Dolphin Imaging & Management Solution, Patterson Technology, Chatswoth, CA, USA). Derived from theses registrations the final treatment plan was determined and the intermediate and final wafer was fabricated.

Surgical technique

The surgical procedure was conducted in general anaesthesia with nasotracheal intubation, supplemented by local anaesthesia. The BSSO was carried out according to the modified technique described by Hunsuck [21]. The distal segment of the mandible was thoroughly mobilized and positioned in the intermediate wafer. Temporary IMF was initiated by 0.4 mm wires and elastic,

before the proximal segment was positioned into the correct position in the temporomandibular fossa. The mandible was stabilized at the vertical osteotomy line with L-shaped, Y-shaped or 2 straight 2 mm titanium plates and 5 mm screws (Stryker Leibinger, Freiburg, Germany). The type of rigid fixation was chosen by an individual preference of the surgeon. Moreover, at the anterior part of the mandibular ramus, a 2-hole 2 mm plate and 5 mm screws were used as supplementary fixation of the osteotomy. The temporary IMF was released and the occlusion in the intermediate wafer was checked. The mucosa was readapted and sutured with resorbable sutures (Vicryl 3-0, Ethicon, Norderstedt, Germany).

The segmental Le Fort I osteotomies were performed as described by Bell [22] with vertical interdental osteotomies mesial to the canines connected to a U-shaped osteotomy in the palate. After mobilization of the segments the final wafer was ligated to the teeth in the maxilla with 0.4 mm wires and elastic. After verifying the new position of the maxilla in all three dimensions, the maxilla was stabilized with four to six L-shaped 1.7 mm titanium plates (Stryker Leibinger, Freiburg, Germany) at the zygomatic buttresses, the anterior aspect of the maxilla, and at the pyriform aperture.

In the anterior nasal spine and subcortical in the symphysis region a 0.6 mm skeletal titanium ligature was inserted as a skeletal elastic IMF. The ligature in the maxilla was inserted through the vestibular incision, whereas the ligature in the mandible was inserted using a vertical incision through the mucosa and muscle in the symphysis region. The ligatures were cut and bent hook-shaped at the level of the brackets to facilitate the application of the postoperative skeletal elastic IMF (Figure 1 and 2). The mucosa was readapted and sutured with resorbable sutures. All patients received intraoperative prophylactic antibiotics and glucocorticosteroids and the final wafer was maintained for 6 weeks postoperatively.

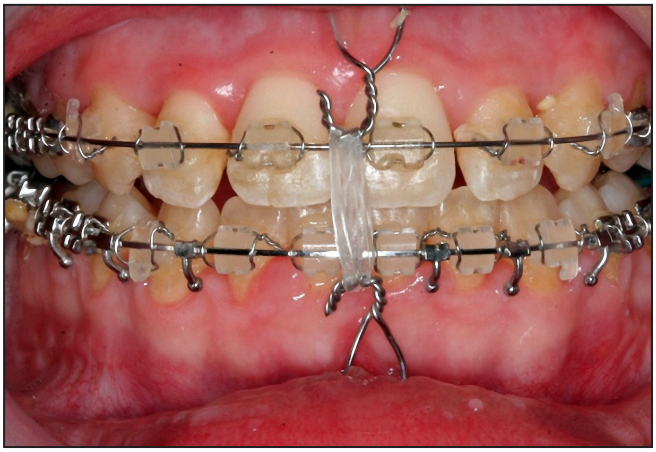

Figure 1. Photograph showing skeletal wires at the symphysis and at the anterior nasal spine.

Follow-up regimen

The patients were included in a follow-up program involving 1 day, 1 week, 3 weeks, 8 weeks (T2/baseline), 6 month, and 18 month (T3/follow-up) postoperatively at the Department of Oral and Maxillofacial Surgery, Aalborg University Hospital, Aalborg, Denmark (Figure 3). Additionally, the patients were included in an individual follow-up program by their orthodontist. The skeletal elastic IMF was activated starting one week postoperatively by connecting the 2 wires from the symphysis to the anterior nasal spine with 3 elastics and worn during 24 hours a day for the following 8 weeks. The patients were allowed to deactivate the IMF 3 times a day for 1 hour duration during mealtimes and oral hygiene. The following 8 weeks the skeletal elastic IMF was only used at night.

Outcome

The primary outcome measures were:

- Skeletal mandibular advancement, defined as the horizontal changes at B-point and pogonion (Pog) between T2/baseline and T1/preoperative;
- Skeletal postsurgical relapse after mandibular advancement, defined as the horizontal change of B-point and Pog between T3/follow-up and T2/baseline.

Figure 2. Lateral cephalometric radiograph illustrating skeletal elastic intermaxillary fixation.

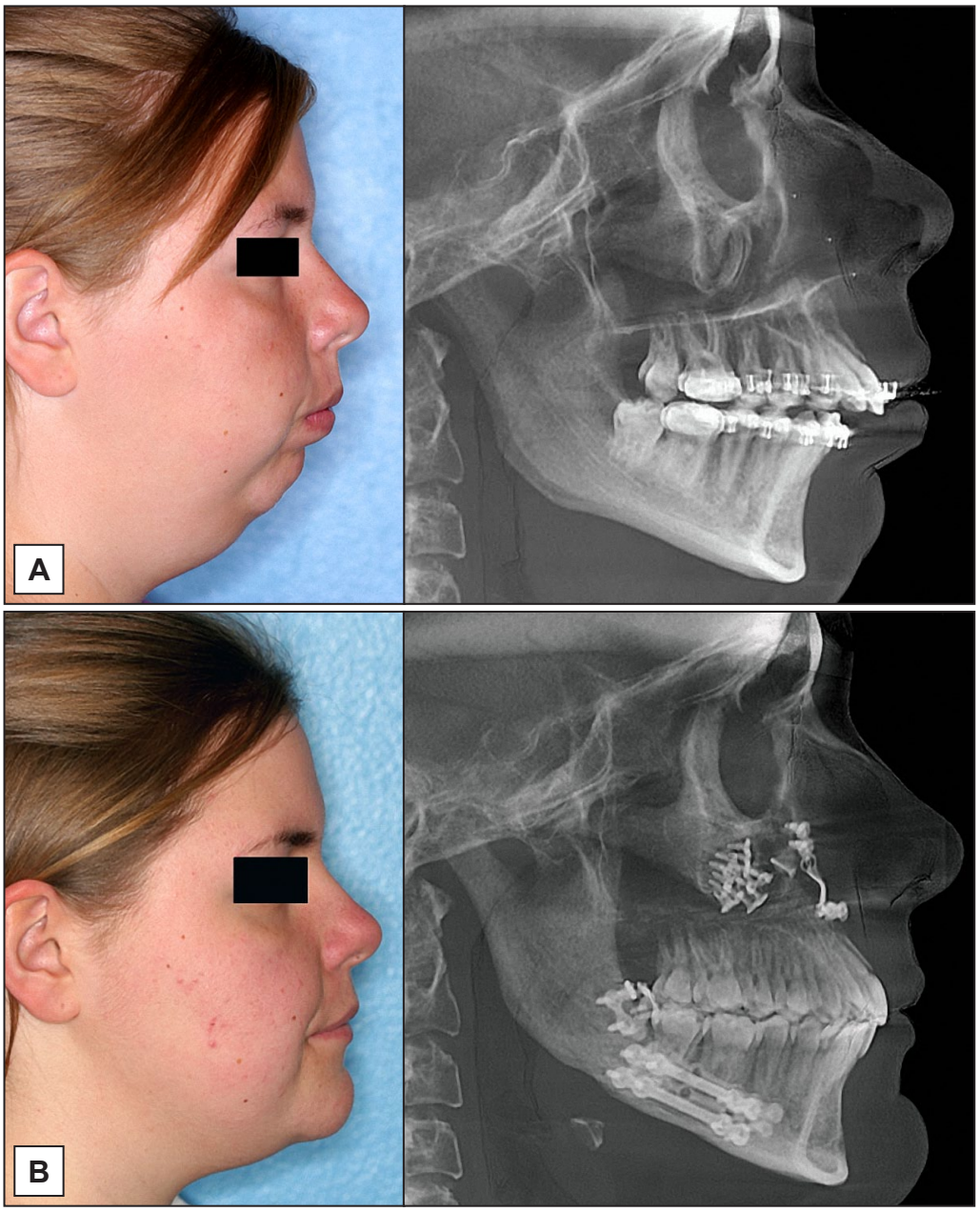

Figure 3. Clinical and radiographic pictures of a patient treated with bimaxillary orthognathic surgery for correction of a skeletal Class II malocclusion.
A = preoperative; B = 18 months postsurgery.

Radiographical examination

To evaluate the stability after BSSO, digital lateral cephalometric radiographs (Orthoceph OC200D, Instrumentarium Dental, Tuusula, Finland) were obtained 14 days preoperatively (T1/preoperative), 8 weeks postoperatively (T2/baseline), and approximately 18 month after surgery (T3/follow-up). Reference planes and landmark identification were performed by the principal investigator using Cliniview 7.0.1 (Instrumentarium Dental, Tuusula, Finland) and the radiographs were corrected for magnification factor using the known distance of the ruler on the radiographs. Magnification, brightness and contrast were used for image enhancement.

An X-Y cranial base coordinate system was constructed on the lateral cephalometic radiographs. The Sella-Nasion line represented the x-axis. A line perpendicular to the x-axis at Sella represented the y-axis. B-point and Pog measurements, were used to evaluate skeletal relapse (Figure 4). MP-angle was defined as the angle between the Sella-Nasion-line and the Gonion-Gnathion-line (mandibular plane) and was used to define the vertical facial type [23]. The patients were assigned in to short facial type (MP-angle < 27º), average facial type (MP-angle 27 - 36º) and long facial type (≥ 37º).

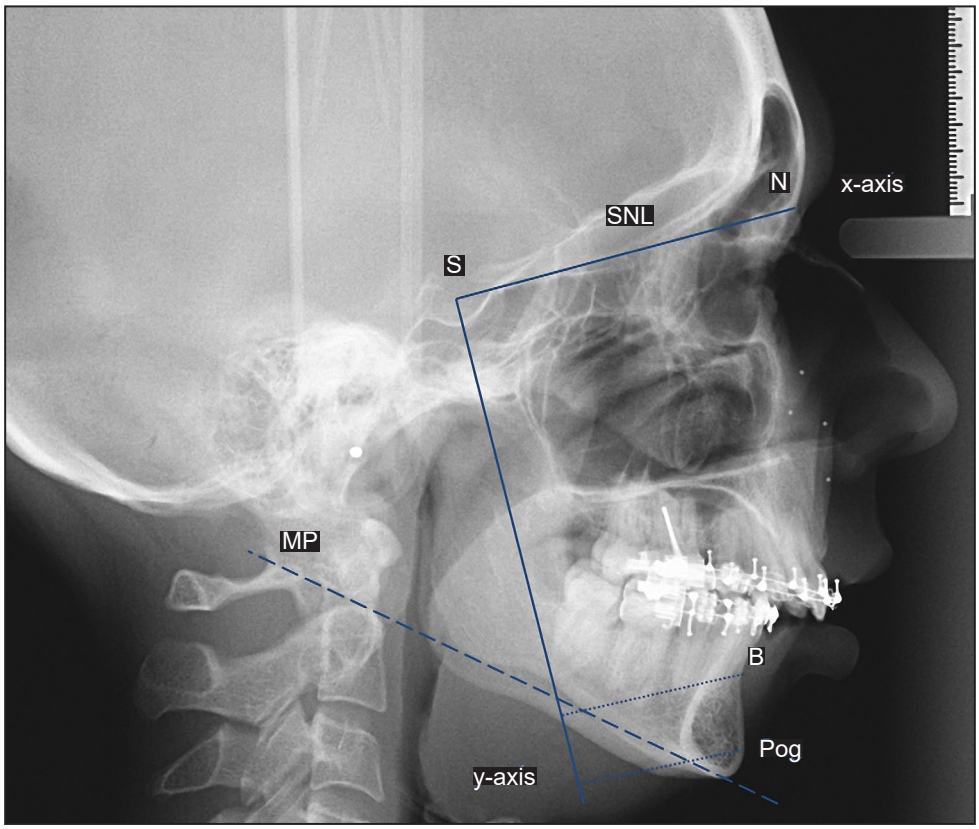

Figure 4. Lateral cephalometric radiograph illustrating landmarks and measurements used for the cephalometric analysis.
N = nasion; S = sella; B = B-point; Pog = pogonion; SNL = sella-nasion line; MP = mandibular plane.

Statistical analysis

Analyses were performed in Stata version 13.0. P-values below 0.05 were considered statistically significant. Categorical variables are summarised as frequencies and continuous variables as mean (M) and standard deviation (SD) plus minimum and maximum. Differences in skeletal advancement and relapse between facial types were analyzed using median tests. Pearson's correlations were computed for the relationship between advancement and relapse at B-point and Pog. Equality of the correlation coefficients between the average and long facial types was tested using Stata's module Cortesti. Comparisons were made between the average and long facial types because there are only two patients with short facial type.

RESULTS

General characteristics of the population are presented in Table 1. The mean follow-up time after surgery was 19.5 months (range 17 to 30). The mean advancement at B-point and Pog were 11.6 mm (range 10.1 to 14.8) and 13.5 mm (range 10.1 to 17.3), respectively (Table 2). Relapse at follow-up was -1.3 mm (11%) at B-point and -1.6 mm (12%) at Pog (Table 2). Two patients were categorized as short facial types with a mean relapse of -1.6 mm (14%) at B-point and -1.9 mm (16%) at Pog. In the average facial type group, 12 patients were included with a mean relapse of -1 mm (9%) at B-point and -1 mm (8%) at Pog. Nineteen patients were characterized as long facial types and presented a mean relapse of -1.5 mm (13%) at B-point and -1.9 mm (14%) at Pog (Table 2).

Table 1. Demographics of patients

Sex		Age (years)		Follow-up (months)	
Female	Male	Mean (SD)	Min; max	Mean (SD)	Min; max
Mean (SD; %)					
20 (60; 61)	13 (39; 39)	23.15 (6.62)	16; 46	19.45 (2.43)	17.2; 30.13

SD = Standard deviation.

Table 2. Data of skeletal advancement and relapse in all patients and within the different facial types

			All patients (n = 33)	Short (n = 2)	Average (n = 12)	Long (n = 19)	P-value
Advancement (mm)	B-point	Mean (SD)	11.62 (1.41)	11.45 (1.99)	11.67 (1.56)	11.61 (1.36)	0.88
		Min; max	10.01; 14.75	10.04; 12.85	10.01; 14.15	10.21; 14.75	
	Pogonion	Mean (SD)	13.51 (2.26)	12.55 (3.51)	12.79 (2.27)	14.06 (2.11)	0.18
		Min; max	10.06; 17.33	10.06; 15.03	10.26; 16.63	11.01; 17.33	
Relapse (mm)	B-point	Mean (SD)	-1.31 (0.72)	-1.63 (0.75)	-1.04 (0.57)	-1.45 (0.78)	0.02[a]
		Min; max	-3.17; -0.24	-2.16; -1.10	-2.47; -0.29	-3.17; -0.24	
	Pogonion	Mean (SD)	-1.58 (1.02)	-1.90 (0.72)	-1.00 (0.75)	-1.89 (1.06)	0.11
		Min; max	-3.86; -0.1	-2.50; -1.48	-2.88; -0.2	-3.86; -0.1	
Relapse (%)	B-point	Mean (SD)	11.43 (6.4)	13.88 (4.14)	8.98 (5.41)	12.72 (6.9)	0.04[a]
		Min; max	2.04; 24.44	10.96; 16.81	2.66; 24.29	2.04; 24.44	
	Pogonion	Mean (SD)	11.76 (7.81)	15.67 (1.36)	7.80 (6.02)	13.85 (8.33)	0.01[a]
		Min; max	0.75; 32.49	14.71; 16.63	1.71; 24.55	0.75; 32.49	

[a]Statistically significant at level $P \leq 0.05$, Median tests.
SD = Standard deviation.

The skeletal advancements were not significantly different between the average and long facial type groups (P = 0.9 at B-point and P = 0.2 at Pog). In contrast, the relapse in mm in the long facial type group is significantly larger than in the average facial type group at B-point (P = 0.02) but not at Pog (P = 0.1). The difference between the two groups is significant when looking at percentage relapse (P = 0.04 at B-point and P = 0.05 at Pog). The correlation between the amount of advancement and relapse at B-point and Pog was very weak (Figure 5) No patients were reoperated.

DISCUSSION

The skeletal stability after large mandibular advancement (> 10 mm) with BSSO and skeletal elastic IMF was retrospectively assessed in 33 patients. Measurements on lateral cephalometric radiographs obtained preoperatively, 8 weeks postsurgical, and after a mean follow-up of 19.5 months demonstrated a mean postsurgical skeletal relapse of 1.3 mm (11%) at B-point and 1.6 mm (12%) at Pog, after a mandibular advancement of 11.6 mm and 13.5 mm, respectively.

Skeletal relapse after BSSO for mandibular advancement is a complex multifactorial phenomenon, where factors as the amount of advancement, the type and material of fixation, low and high mandibular plane angle, condylar resorption, control of the proximal segment, soft tissue and muscle tension, remaining growth and remodelling, skills and experience of the surgeon may contribute to skeletal relapse [24-26].

A systematic review regarding skeletal stability after BSSO advancement surgery found a short-term (< 1.5 years) skeletal relapse with the use of miniplates between 1.5% and 18% at B-point and between 1.4% and 18.7% at Pog, in patients with a advancement of 7 mm or less [6]. Another study evaluated the skeletal stability following maxillary impaction and mandibular advancement with BSSO [27]. Their study included 29 patients with a Class II skeletal malocclusion with an initial mean-age at baseline of 22.6 years and a postsurgical follow-up of 25 month. They found a mean advancement of the mandible of 10.7 mm (range 8.5 to 12.7) at menton, with a mean skeletal relapse of -4 mm. The amount of skeletal relapse in the present study is comparative to other studies with mandibular advancements of 7 mm or less [6]. However, it seems like the amount of skeletal relapse is reduced compared to studies with mandibular advancements of 7 mm or more [27].

The mandibular plane angle is also a factor that may contribute to skeletal relapse. Postsurgical skeletal stability of patients with normal mandibular plane angle and advancements below 7 mm is essentially stable when treated with rigid fixation [9,10]. However, in patients with high mandibular angle and large advancements relapse is seen despite the use of rigid fixation [2,10]. In the present study 12 patients were categorized as average facial type with a relapse of 9% at B-point and 8% at Pog and 19 patients were characterized as long facial types with at relapse of 13% at B-point and 14% at Pog. Skeletal relapse in high mandibular plane angle is most likely related to the myoskeletal balance

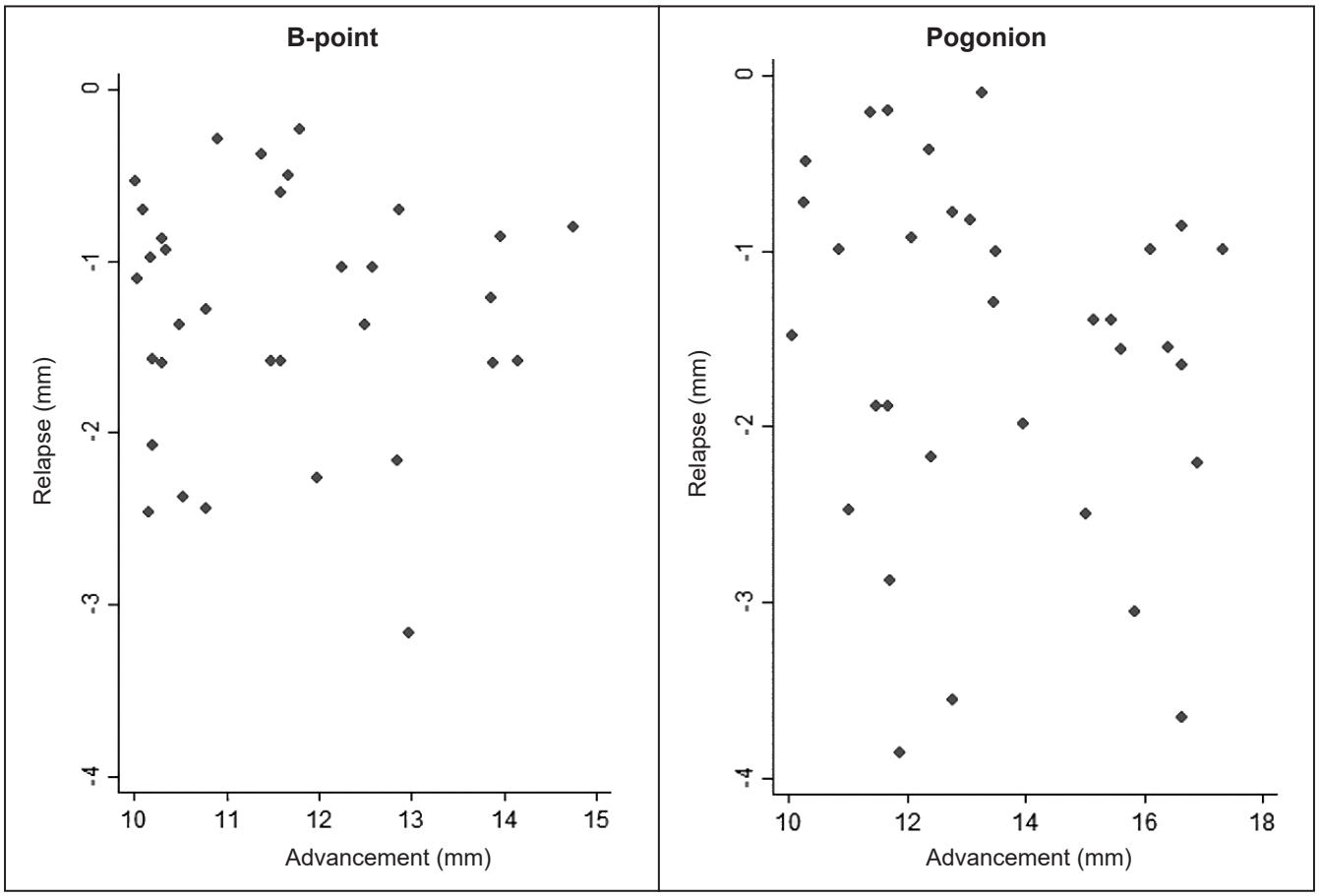

Figure 5. Scatter plot of the correlation between the amount of advancement and relapse. B-point (rho = 0.01) and Pogonion (rho = 0.17). Pearson's correlations.

and the counter-clock wise rotation that can occur during advancement in the high angle cases [8,10]. In patients with larger mandibular advancements, there is as directly proportional increase in the risk of skeletal relapse, due to the perimandibular soft-tissue tension [9,12]. Condylar resorption can occur after mandibular advancement surgery and may give rise to long-term relapse [28]. Patients in risk of condylar resorption are young women with a high mandibular plane angle, and there is a positive correlation between the amount of advancement and condylar resorption [28]. To minimize skeletal relapse, BSSO in combination with postoperative skeletal elastic intermaxillary fixation has been advocated [16-18]. The skeletal elastic intermaxillary fixation in the present study is used for 16 weeks after surgery. Theoretically, the skeletal elastic intermaxillary fixation counteracts the perimandibular muscle and soft tissue tension that occur after advancements and counter-clockwise rotation of the mandible and contribute to reduce condylar resorption. BSSO and distraction osteogenesis are the most common techniques used for advancement of the retrognathic mandible. Both distraction osteogenesis and BSSO have demonstrated similar amount of relapse for mandibular advancement up to 10 mm [15,26]. In large mandibular advancement (10 mm or more) it seems that distraction osteogenesis is less prone to relapse compared to BSSO [13]. The potential promise of distraction osteogenesis is that because of the lengthening of the mandible occurs slowly, the soft tissue stretch associated with the lengthening can be more readily accommodated to the masticatory system. Moreover, distraction osteogenesis reduces the incidence of neurosensory disturbances of the inferior alveolar nerve after advancement of the retrognathic mandible compared with BSSO [24]. However, mandibular distraction osteogenesis is associated with a higher incidence of complications and increased patient discomfort compared to BSSO [13,14].

CONCLUSIONS

Bilateral sagittal split osteotomy is characterized as a stable surgical procedure to correct Class II malocclusion. The present study showed a limited amount of skeletal relapse in every vertical facial type undergoing large mandibular advancement

with bilateral sagittal split osteotomy and postsurgical skeletal elastic intermaxillary fixation for 16 weeks. Consequently, bilateral sagittal split osteotomy in combination with skeletal intermaxillary fixation can therefore be an alternative to distraction osteogenesis in large mandibular advancements. However, due to the reduced number of patients in this retrospective study, further investigation involving larger patient samples with a control group, and long-term follow-up are needed before final conclusions can be made regarding this topic.

ACKNOWLEDGMENTS AND DISCLOSURE STATEMENTS

The authors report no conflicts of interest related to this study.

REFERENCES

1. Bailey L', Cevidanes LH, Proffit WR. Stability and predictability of orthognathic surgery. Am J Orthod Dentofacial Orthop. 2004 Sep;126(3):273-7. [Medline: 15356484] [PMC free article: 3681098] [doi: 10.1016/j.ajodo.2004.06.003]
2. Proffit WR, Turvey TA, Phillips C. The hierarchy of stability and predictability in orthognathic surgery with rigid fixation: an update and extension. Head Face Med. 2007 Apr 30;3:21. [Medline: 17470277] [PMC free article: 1876453] [doi: 10.1186/1746-160X-3-21]
3. Trauner R, Obwegeser H. The surgical correction of mandibular prognathism and retrognathia with consideration of genioplasty II. Operating methods for microgenia and distoclusion. Oral Surg Oral Med Oral Pathol 1957 Jul;10(7): 677-89. [Medline: 13452398] [doi: 10.1016/S0030-4220(57)80063-2]
4. Bell WH, Schendel SA. Biologic basis for modification of the sagittal ramus split operation. J Oral Surg. 1977 May;35(5):362-9. [Medline: 403263]
5. Wyatt WM. Sagittal ramus split osteotomy: literature review and suggested modification of technique. Br J Oral Maxillofac Surg. 1997 Apr;35(2):137-41. [Medline: 9146874] [doi: 10.1016/S0266-4356(97)90691-4]
6. Joss CU, Vasalli IM. Satbility after bilateral sagittal split osteotomy advancement surgery with rigid internal fixation: a systematic review. J Oral Maxillofacial Surg. 2009 Feb;67(2):301-13. [Medline: 19138603] [doi: 10.1016/j.joms.2008.06.060]
7. Blomqvist JE, Isaksson S. Skeletal stability after mandibular advancement: a comparison of two rigid internal fixation techniques. J Oral Maxillofac Surg. 1994 Nov;52(11):1133-7. [Medline: 7965307] [doi: 10.1016/0278-2391(94)90529-0]
8. Epker BN, Wessberg GA. Mechanisms of early skeletal relapse following surgical advancement of the mandible. Br J Oral Maxillofac Surg 1982 Sep;20(3):175-82. [Medline: 6958313] [doi: 10.1016/S0007-117X(82)80035-8]
9. Gassmann CJ, van Sickels JE, Thrash WJ. Causes, location, and timing of relapse following rigid fixation after mandibular advancement. J Oral Maxillofac Surg 1990 May;48(5):450-4. [Medline: 2329394] [doi: 10.1016/0278-2391(90)90229-U]
10. Mobarak KA, Espeland L, Krogstad O, Lyberg T. Mandibular advancement surgery in high-angle and low-angle class II patients: Different long-term skeletal responses. Am J Orthod Dentofacial Orthop 2001 Apr;119(4):368-81. [Medline: 11298310] [doi: 10.1067/mod.2001.110983]
11. Proffit WR, Turvey TA, Philips C. Orthognathic surgery: a hierarchy of stability. Int J Adult Orthod Orthognath Surg. 1996;11(3):191-204. [Medline: 9456622]
12. Will LA, West RA. Factors influencing the stability of the sagittal split osteotomy for mandibular advancement. J Oral Maxillofac Surg 1989 Aug;47(8):813-8. [Medline: 2746390] [doi: 10.1016/S0278-2391(89)80039-4]
13. Schreuder WH, Jansma J, Bierman MWJ, Vissnik A. Distraction osteogenesis versus bilateral sagittal split osteotomy for andvancement of the retrognathic mandible: a review of the litterature. Int J Oral Maxillofac Surg. 2007 Feb;36:103-110. [Medline: 17270397] [doi: 10.1016/j.ijom.2006.12.002]
14. Verlinden CR, van de Vijfeijken SE, Tuinzing DB, Becking AG, Swennen GR. Complications of mandibular distraction osteogenesis for acquired deformities: a systematic review of the literature. Int J Oral Maxillofac Surg. 2015 Aug;44(8): 956-64. [Medline: 25842053] [doi: 10.1016/j.ijom.2014.12.008]
15. Baas EM, Bierenbroodspot F, de Lange J. Skeletal stability after bilateral sagittal split osteotomy or distraction osteogenesis of the mandible: a randomized clinical trial. Int J Oral Maxillofac Surg. 2015 May;44(5):615-20. [Medline: 25595452] [doi: 10.1016/j.ijom.2014.12.011]
16. Ellis E 3rd, Gallo WJ. Relapse following mandibular advancement with dental plus skeletal maxillomandibular fixation. J Oral Maxillofac Surg. 1986 Jul;44(7):509-15. [Medline: 3459835]
17. Komori E, Aigase K, Sugisaki M, Tanabe H. Skeletal fixation versus skeletal relapse. Am J Orthod Dentofacial Orthop. 1987 Nov;92(5):412-21. [Medline: 3479009] [doi: 10.1016/0889-5406(87)90262-9]
18. Hartlev J, Godtfredsen E, Andersen NT, Jensen T. Comparative Study of Skeletal Stability between Postoperative Skeletal Intermaxillary Fixation and No Skeletal Fixation after Bilateral Sagittal Split Ramus Osteotomy: an 18 Months Retrospective Study. J Oral Maxillofac Res. 2014 Apr 1;5(1):e2. [Medline: 24800052] [PMC free article: 4007368] [doi: 10.5037/jomr.2014.5102]

19. Perez D, Ellis E 3rd. Sequencing bimaxillary surgery: mandible first. J Oral Maxillofac Surg. 2011 Aug;69(8):2217-24. [Medline: 21292376] [doi: 10.1016/j.joms.2010.10.053]
20. Arnett GW, Maclaugin RP. The clinical examination. In: Arnett and Maclaugins, editors. Facial and dental Planning for orthodontist and oral surgeons, 1st Edition. Elsevier Health Sciences; 2003. p. 47-78.
21. Hunsuck EE. A modified intraoral sagittal splitting technic for correction of mandibular prognathism. J Oral Surg. 1968 Apr;26(4):250-3. [Medline: 5237786]
22. Bell WH. Le Forte I osteotomy for correction of maxillary deformities. J Oral Surg. 1975 Jun;33(6):412-26. [Medline: 1055202]
23. Karlsen AT. Craniofacial growth differences between low and high MP-SN angle males: a longitudinal study. Angle Orthod. 1995;65(5):341-50. [Medline: 8526293]
24. Al-Moraissi EA, Ellis E 3rd. Bilateral Sagittal Split Ramus Osteotomy Versus Distraction Osteogenesis for Advancement of the Retrognathic Mandible. J Oral Maxillofac Surg. 2015 Aug;73(8):1564-74. [Medline: 25857283] [doi: 10.1016/j.joms.2015.01.003]
25. den Besten CA, Mensink G, van Merkesteyn JP. Skeletal stability after mandibular advancement in bilateral sagittal split osteotomies during adolescence. J Craniomaxillofac Surg. 2013 Jul;41(5):e78-82. [Medline: 23253633] [doi: 10.1016/j.jcms.2012.11.012]
26. Ow A, Cheung LK. Bilateral sagittal split osteotomies and mandibular distraction osteogenesis: a randomized controlled trial comparing skeletal stability. Oral Surg Oral Med Oral Pathol Oral Radiol Endod. 2010 Jan;109(1):17-23. [Medline: 19875317] [doi: 10.1016/j.tripleo.2009.07.030]
27. Arpornmaeklong P, Shand JM, Heggie AA. Skeletal stability following maxillary impaction and mandibular advancement. Int J Oral Maxillofac Surg. 2004 Oct;33(7):656-63. [Medline: 15337178] [doi: 10.1016/j.ijom.2004.01.004]
28. Moore KE, Gooris PJ, Stoelinga PJ. The contributing role of condylar resorption to skeletal relapse following mandibular advancement surgery: report of five cases. J Oral Maxillofac Surg. 1991 May;49(5):448-60. [Medline: 2019890] [doi: 10.1016/0278-2391(91)90166-J]

To cite this article:
Schwartz K, Rodrigo-Domingo M, Jensen T.
Skeletal Stability after Large Mandibular Advancement (> 10 mm) with Bilateral Sagittal Split Osteotomy and Skeletal Elastic Intermaxillary Fixation
J Oral Maxillofac Res 2016;7(2):e5
URL: http://www.ejomr.org/JOMR/archives/2016/2/e5/v7n2e5.pdf
doi: 10.5037/jomr.2016.7205