

# Frequency and Clinical Significance of Incidental Findings on CBCT Imaging: a Retrospective Analysis of Full-Volume Scans

Charis Theodoridis<sup>1</sup>, Spyros Damaskos<sup>2</sup>, Christos Angelopoulos<sup>3</sup>

<sup>1</sup>Department of Preventive Dentistry - Periodontology and Implant Biology, Aristotle University of Thessaloniki, 3 Kavalas Str., 565625, Sykies, Thessaloniki, Greece. Email: ht\_auth.dent@yahoo.com

<sup>2</sup>Department of Oral Diagnosis and Radiology, Dental School of Athens, National and Kapodistrian University of Athens, 2 Thivon Str, 11527, Goudi, Athens, Greece. Email: sdamask@dent.uoa.gr

<sup>3</sup>Department of Oral Diagnosis and Radiology, Dental School of Athens, National and Kapodistrian University of Athens, 2 Thivon Str, 11527, Goudi, Athens, Greece. Email: angelopoulosc@gmail.com

## Corresponding Author:

Spyros Damaskos

Department of Oral Diagnosis and Radiology, Dental School of Athens

National and Kapodistrian University of Athens

2 Thivon Str, 11527, Goudi, Athens

Greece

Phone: +30 210 2713402

Fax: +30 6944541529

E-mail: [sdamask@dent.uoa.gr](mailto:sdamask@dent.uoa.gr)

## ABSTRACT

**Objectives:** This retrospective study aims to identify incidental findings in cone-beam computed tomography scans of patients irradiated for preoperative evaluation for implant placement and obtained using the same imaging unit as well as the same field of view. The incidence of each incidental finding, as well as the overall incidence, were calculated and the findings were ranked according to their clinical significance.

**Material and Methods:** A total of 741 cone-beam computed tomography (CBCT) examinations with extended field of view (15 x 15 cm) were retrospectively evaluated for incidental findings (IFs). These were identified, recorded, classified as to their location, and ranked according to their clinical significance.

**Results:** The vast majority of CBCT examinations presented at least one IF, resulting in a surprisingly high prevalence in total. If extreme anatomical variants are considered (nasal septum deviation, sinus septations etc.), the cumulative prevalence exceeds 99%. IFs of major significance, that may require immediate attention, are beyond 10% in frequency.

**Conclusions:** We found high prevalence of incidental findings on cone-beam computed tomography examinations performed for preoperative evaluation for implant placement (99.5% if anatomical variants included). Most incidental findings were of minor significance. Although the number of incidental findings that require immediate attention is relatively low, there is a considerable number of cases that need periodic evaluation and/or referral.

**Keywords:** clinical relevance; cone-beam computed tomography; dental implants; incidental findings.

Accepted for publication: 31 March 2024

### To cite this article:

Theodoridis C, Damaskos S, Angelopoulos C.

Frequency and Clinical Significance of Incidental Findings on CBCT Imaging: a Retrospective Analysis of Full-Volume Scans

J Oral Maxillofac Res 2024;15(1):e5

URL: <http://www.ejomr.org/JOMR/archives/2024/1/e5/v15n1e5.pdf>

doi: [10.5037/jomr.2024.15105](https://doi.org/10.5037/jomr.2024.15105)

## INTRODUCTION

Given the inherent limitations of two-dimensional approach in dental imaging, the advent of cone-beam computed tomography (CBCT) with the multi-planar imaging of the craniomaxillofacial complex that it provides, gave rise to significantly increased diagnostic accuracy and validity in oral and maxillofacial radiology [1]. Therefore, this increase, obtained due to the three-dimensional visualization of the structures of this anatomical area, has led to the identification of radiological findings largely incidental and, more or less unexpected, in relation to the reason for performing the radiological examination [2]. Some of these incidental findings (IFs) are easily recognizable and can be identified by anatomical and radiological criteria (e.g., mucosal thickening, tonsiloliths, etc.). On the other hand, such an IF presence could cause a diagnostic dilemma, which may require further investigation through additional clinical assessment, different imaging methods and/or paraclinical tests [2,3].

Such IFs are also present - to a different extent for each imaging modality - in medical radiology. A classic example of such an IF is the identification of pulmonary nodules during examination of a chest X-ray or, more commonly, a medical computed tomography (CT) scan that includes the lungs [4]. In the systematic review of 26 multi-slice computed tomography (MSCT) studies by Lumbreras et al. [4], which covered the entire spectrum of imaging diagnostic tests in medicine, the mean overall frequency of IFs in MSCT was found to be 31.1% (95% CI [confidence interval] = 20.1 to 41.9%). Also, worth mentioning is the multicentre study by Rogers et al. [5], in which the prevalence of IFs in 15831 MSCT examinations of the head was found to be up to 4%. Wisely, the authors acknowledged the legal and bioethical aspects that arise when managing and reporting these findings to patients and their families.

Despite the inability of CBCT to clearly present soft tissue, compared to MSCT, on account of its lower contrast resolution, and hence its probable decreased capacity towards distinguishing of findings among soft tissue differences, the detection frequency of IFs on CBCT is not inferior to that of MSCT, since it usually exceeds 50% [3,6-19].

The existing diversity among IFs that can be found on CBCT examinations covers a wide range of irradiated structures. These are both, the maxilla and the mandible, paranasal sinuses, nose, pharynx and upper airway, temporomandibular joints (TMJ),

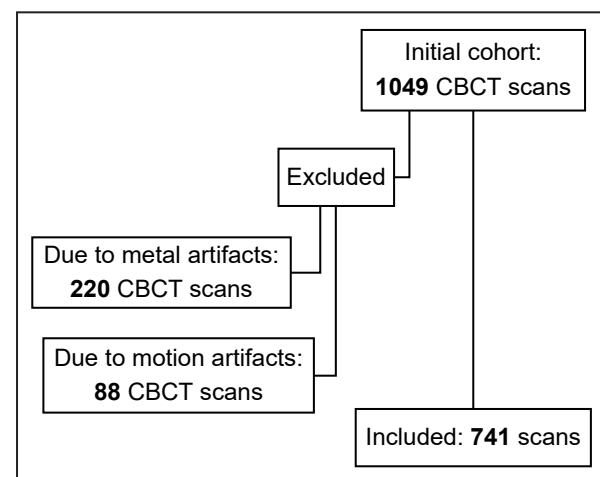
skull base, facial bones, spine, and the soft and hard tissues of the neck. These findings can be classified based on their anatomic location and clinical significance [2].

The present retrospective study aims to identify incidental findings in cone-beam computed tomography scans of patients irradiated for preoperative evaluation for implant placement, having been obtained by using the same imaging unit as well as the same field of view. The incidence of each incidental finding, as well as the overall incidence, were calculated and the findings were ranked according to their clinical significance.

## MATERIAL AND METHODS

### Subjects

A total of 1049 full-volume (15 x 15 cm, field of view [FOV]) CBCT examinations were performed at the Aristotle University of Thessaloniki (Thessaloniki, Greece) in patients older than 18 years for routine radiographic evaluation before implant surgery, from May 5, 2014 to May 31, 2017, were included in this study. Informed consent was obtained prior to all clinical and imaging procedures. In total 1049 CBCT scans were selected and retrospectively evaluated. Of these, 308 scans, with poor diagnostic information due to artifacts presence were excluded from this study (Figure 1). Ultimately, a total of 741 CBCT examinations that met the inclusion and exclusion criteria were evaluated. All CBCT examinations were submitted for interpretation to a radiologic interpretation and reporting service (Maxillofacial Radiology Consultants<sup>®</sup>; New York, NY, USA). Due to the retrospective nature of this study, ethical approval was not required from the Aristotle University of Thessaloniki.



**Figure 1.** Eligibility criteria.

**CBCT imaging**

All patients were irradiated by the same dental imaging unit - Galileos® Comfort Plus three-dimensional CBCT scanner (Sirona Dental Systems Inc.; Bensheim, Hessen, Germany) - using the units fixed kV and mA exposure parameters (85 KVp, 5 to 7 mA, FOV 15 x 15 x 15 [spherical volume], voxel size 300 µm), for all examinations. All CBCT scans were evaluated using Invivo™ 6 software (Anatomage; San Jose, CA, USA). After the image reconstruction, 1 mm-thick transverse, coronal, and sagittal sections of both, the maxilla and mandible, as well as panoramic and cross-sectional ones were created. When the TMJs were visible, the 1 mm-thick coronal and sagittal imaging sections of the left and right articulations were also reconstructed.

**Evaluation of the CBCT images**

For each of the 741 CBCT exams, the interpretation of the entire image volume was carried out by the same dentist C.A. (oral radiology specialist, certified by the American Board of Oral and Maxillofacial Radiology). He recorded the findings per anatomical region, in special medical opinions with a standardized structure by Maxillofacial Radiology Consultants®. These opinions reported the findings, also classified by anatomic region and specifically into findings located in the maxilla, mandible, nose and paranasal cavities, spine, neck, and TMJ structures, as well as the relevant recommendations.

Retrospectively, these opinion-based radiological findings were assessed, standardized, and recorded as

qualitative variables in processed tables/worksheets of Microsoft 365® online program Excel (Microsoft Corporation; Washington, USA) by two independent examiners (C.T., S.D.). The standardization and classification of the findings in specific cells for each category was carried out after discussion and consensus of the researchers. Thus, the following variables were created:

1. Gender;
2. IFs referring to nose, paranasal sinuses, TMJs and endocranium (Table 1);
3. IFs referring to mouth floor, cervical spine, and neck (Table 2);
4. IFs of minor significance;
5. IFs of intermediate significance;
6. IFs of major significance (Table 3).

Since all patients were primarily referred for CBCT examination due to preoperative evaluation for implant placement, findings of dental or periodontal origin were excluded from further analysis as they were not considered “incidental”.

**Statistical analysis**

The IFs reported in Tables 1 and 2 were statistically processed using IBM® SPSS® Statistics for Windows version 23.0 (IBM Corp.; Armonk, New York, USA) and the frequency and relative frequency of each finding was calculated separately. In cases where TMJ was not visible in the CBCT-volume, the corresponding variables were considered as missing values, and these cases were not considered for the overall calculation of the frequencies associated with the incidental TMJ findings.

**Table 1.** Incidental findings referring to nose, paranasal sinuses, temporomandibular joints (TMJ) and endocranium

Incidental findings	
<b>Nose</b>	Nasal septum deviation, nasal polyp, conchae bullosa, nasal mucosal thickening
<b>Paranasal sinuses</b>	Sinus hypoplasia, sinus aplasia, limited inflammatory changes, moderate-severe inflammatory changes, sinus mucosal thickening, sinus septa, sinus polyp, retention cyst, discontinuity of sinus floor - oroantral fistula, soft tissue pathology on osseous borders, frontal sinus hypoplasia, frontal sinus aplasia, frontal sinus mucosal thickening, frontal sinus inflammatory changes, foreign body/root in sinus, ethmoid cell inflammatory changes, ethmoid cell mucosal thickening, total opacification, paranasal benign entities
<b>TMJ</b>	Mild - moderate degenerative changes, moderate - severe degenerative changes
<b>Endocranium</b>	Internal carotid artery calcification(s), <i>sella turcica</i> enlargement, Sphenoid sinus inflammatory changes, sphenoid sinus mucosal thickening

**Table 2.** Incidental findings referring to mouth floor, cervical spine, and neck

Incidental findings	
<b>Mouth floor</b>	Sialoliths
<b>Cervical spine</b>	Cervical spine degenerative changes
<b>Neck</b>	Tonsiloliths, tonsillar hypertrophy, posterior pharyngeal tonsillar hypertrophy, airway asymmetry, airway narrowing, airway obliteration, stylohyoid complex calcification, thyroid cartilage calcification, extracranial carotid artery calcification(s), other neck calcification(s)

**Table 3.** Classification of incidental findings according to their clinical significance

Clinical significance of incidental findings		
Low	Moderate	High
Antral septations	Nasal mucosal thickening	Soft tissue pathology on osseous borders
Ethmoid sinus mucosal thickening	Nasal polyp	Extracranial carotid artery atheromatic calcifications
Sphenoid sinus mucosal thickening	Maxillary sinus limited inflammatory changes	<i>Sella turcica</i> enlargement
Frontal sinus mucosal thickening	Moderate/severe inflammatory changes of maxillary sinus	Airway asymmetry
Frontal sinus hypoplasia	Total opacification of maxillary sinus	Intracranial carotid artery atheromatic calcifications
Frontal sinus aplasia	Discontinuity of sinus floor	-
Tonsiloliths	Foreign object in maxillary sinus - root in maxillary sinus	-
Stylohyoid ligament calcification	Antral polyp	-
Calcified thyroid cartilage	Ethmoid sinus inflammatory changes	-
Degenerative changes of cervical spine	Sphenoid sinus inflammatory changes	-
Mild - moderate TMJ degenerative changes	Frontal sinus inflammatory changes	-
Moderate - severe TMJ degenerative changes	Paranasal benign entities (tumours)	-
Antral septations	Sialoliths	-
Ethmoid sinus mucosal thickening	Tonsillar hypertrophy	-
Sphenoid sinus mucosal thickening	Posterior pharyngeal tonsillar hypertrophy	-
Frontal sinus mucosal thickening	Airway narrowing	-
Frontal sinus hypoplasia	Other neck calcifications	-
Frontal sinus aplasia	Nasal mucosal thickening	-

TMJ = temporomandibular joint.

**RESULTS**

Out of the 741 patients who underwent CBCT examination, 329 (44.4%) were males and 412 were females (55.6%). The total number of IFs detected in all CBCT scans was 2715 findings in 741 patients, showing an average of 3.66 findings per patient. Only 81 out of 741 patients (10.93%) were found without any pathological IF. If several anatomical variations such as scoliosis/deviation of the nasal septum, sinus hypoplasia and/or aplasia and bony septa of the paranasal sinuses are taken into account, then only 4 patients do not present IFs; with the overall incidence of findings reaching up to 99.5%.

The frequencies and relative frequencies of pathologic IFs, as well as anatomic variations identified in the anatomical regions of the nose, paranasal sinuses, cranial sinuses, and endocranium are presented in Table 4. The frequencies and relative frequencies of TMJ-related findings were calculated based on a sample of 663 TMJs, since only these were sufficiently depicted in the CBCT tomographic field. Accordingly, all the frequencies and IFs, as well as anatomic variations identified in the anatomical

regions of the floor of the mouth, spine, and neck are presented in Table 5.

All detected IFs were classified into 3 categories, according to their clinical significance. Thus, IFs of low clinical significance do not require further action; IFs of moderate clinical significance usually require follow-up and occasionally referral; and finally, IFs of high clinical significance require immediate attention and appropriate referral/intervention. Table 3 illustrates the classification of detected IFs according to their clinical significance. Furthermore, representative IFs images of high clinical significance are shown in Figures 2 and 3.

**DISCUSSION**

It is reasonable to expect that CBCT may reveal more diagnostic information than the relevant two-dimensional images, resulting in a rapidly increasing perspective in dental radiology [7]; as the frequency of the type of IFs has been shown to increase with increasing FOV [20]. Interestingly, in our retrospective study of CBCT scans of patients referred for evaluation of implant placement, IFs were observed at a high overall frequency.

**Table 4.** Frequencies and relative frequencies of incidental findings identified in the anatomical regions of the nose, paranasal sinuses, temporomandibular joints and endocranium

Incidental finding	Frequency*	Relative frequency* (%)
Nasal septum deviation	611	82.5
Conchae bullosa	113 (45)	15.3 (6.1)
Nasal mucosal thickening	107 (94)	14.5 (1.8)
Nasal polyp	7	0.9
Sinus mucosal thickening	358 (180)	48.3 (24.3)
Retention cyst	58 (5)	7.9 (0.7)
Sinus hypoplasia	13 (6)	1.7 (0.8)
Sinus aplasia	1	0.1
Sinus septa	17	2.3
Limited inflammatory changes	37 (7)	4.9 (0.9)
Moderate-severe inflammatory changes	64 (27)	8.6 (3.6)
Total opacification	13 (2)	1.8 (0.3)
Discontinuity of sinus floor - oroantral fistula	9 (1)	1.2 (0.1)
Foreign body/root in sinus	1	0.1
Sinus polyp	15 (3)	2 (0.4)
Ethmoid cell mucosal thickening	12	1.6
Ethmoid cell inflammatory changes	79	10.9
Sphenoid sinus mucosal thickening	23	3.1
Sphenoid sinus inflammatory changes	12	1.6
Frontal sinus mucosal thickening	20	2.7
Frontal sinus inflammatory changes	8	1.4
Frontal sinus hypoplasia	39	5.2
Frontal sinus aplasia	9	1.2
Paranasal benign entities	4	0.5
Soft tissue pathology on osseous borders	1	0.1
<i>Sella turcica</i> enlargement	2	0.3
Internal carotid artery calcification(s)	11 (10)	1.4 (1.3)

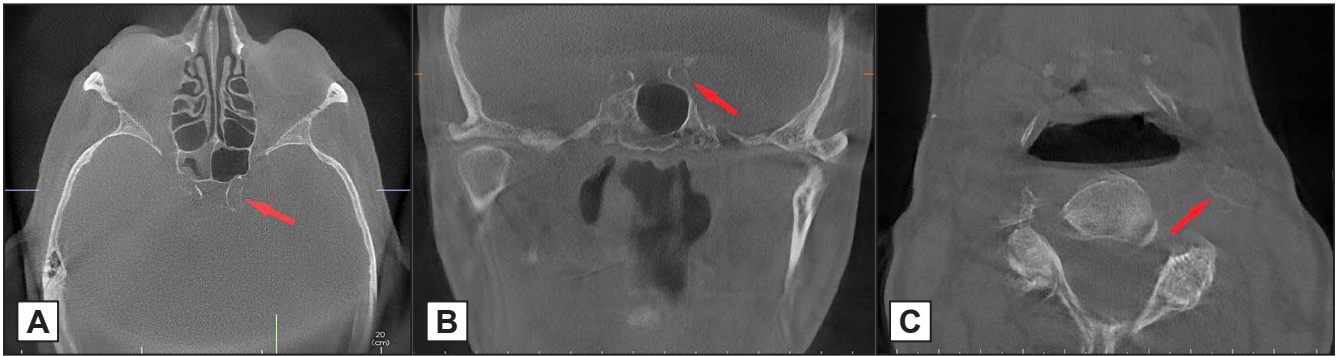\*Values in brackets indicate frequency of bilateral localization.

**Table 5.** Frequencies and relative frequencies of incidental findings identified in the anatomical regions of the floor of the mouth, spine, and neck

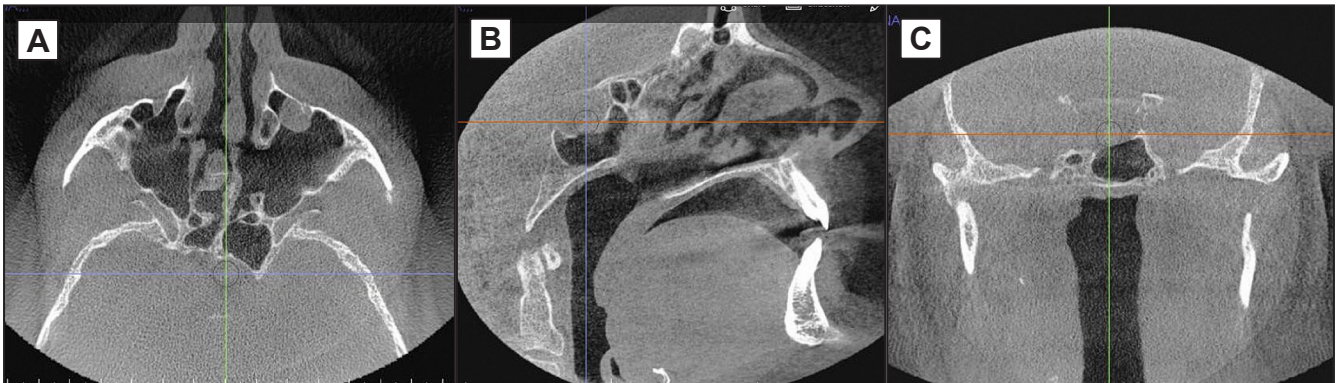
Incidental finding	Frequency*	Relative frequency* (%)
Sialoliths	3	0.4
Tonsillar hypertrophy	17 (13)	2.3 (1.8)
Tonsiloliths	95	12.6
Posterior pharyngeal tonsillar hypertrophy	9	1.2
Airway narrowing	279	37.7
Airway obliteration	2	0.3
Airway asymmetry	3	0.4
Calcification of the stylohyoid ligament	23 (18)	3.1 (2.4)
Calcification of laryngeal thyroid cartilages and/or thyroid complex	107	14.4
Presence of other calcifications in the neck	12	1.6
Degenerative bone changes of the spine	28	3.7
Calcified atheromas within the course of the carotid artery extracranially	77 (30)	10.3 (6.3)

\*Values in brackets indicate frequency of bilateral localization.





**Figure 2.** Atheromatous calcifications (red arrows). A and B intra-cranial localization; C = extra-cranial localization.



**Figure 3.** *Sella turcica* enlargement sections: A = axial; B = coronal; C = sagittal.

More in detail, out of a total of 741 CBCT examinations, a number of 2715 IFs - including anatomical variations - were identified. This indicates a number of 3.6 IFs per patient, whereas Price et al. [8] found 3.2 IFs per patient, and Edwards et al. [14] found that these IFs ranged from 1.3 to 2.9 IFs per CBCT scan.

In particular, only 81 CBCT scans were found without IFs outside the area of interest, this amounts to 89.07% of the cases. If the various anatomical variations are added to the above percentage, then 99.5% of the CBCT examinations investigated showed at least one IF. It's worth noting that only 4 patients out of 741 did not present any IF. However, the most prevalent IFs identified in our study were the nasal septum deviation (82.5%), sinus mucosal thickening (48.3%), airway narrowing (37.7%), conchae bullosa (15.3%) and nasal mucosal thickening (14.5%), being generally findings with not such high clinical significance.

Previous studies on CBCT scans have also shown an IF prevalence of 80 to 90%, even though smaller FOVs were used [2,7,11-13,14,16,18,19]. Our results are also consistent with those of Price et al. [8], Çağlayan et al. [2] and Edwards et al. [14] who reported that the airway was the zone with the highest number of IFs in CBCT examinations, albeit the reported sample-sizes were quite limited. On the other hand, Cha et al. [7] and Rheem et al. [13] reported

much lower IFs incidence in CBCT scans (26.4% and 40.1% respectively), while Drage et al. [16] and Pilska et al. [9] reported an IF incidence of 65%. The reported lower incidence of IFs in the aforementioned studies is attributed to a variety of factors, such as the size of the FOV used. In particular, Drage et al. [16] performed their study using CBCT scans obtained with a 4 x 4 FOV, while Rheem et al. [13] used various FOV sizes to calculate the final frequency. As previously stated, the frequency of the type of incidental findings has been shown to increase with increasing FOV [20], so using a limited FOV, such as 5 x 5 x 6, and/or 8 x 8 x 8 cm, may result in revelation of fewer IFs. That being said, it is noteworthy to report that, due to the single imaging unit used (Galileos® Comfort Plus), the FOV used in our study was 15 x 15 cm (spherical volume) in all of the included scans. Consequently, identifying all possible IFs that may be present in a single volume, results in a most pragmatic approach for each individual patient.

Nevertheless, our findings are in line with past systematic review findings, indicative of high rates of IFs detection; As a matter of fact, the most cited systematic reviews, those of Edwards et al. [21] and Dief et al. [20], found a comparable frequency in the presence of IFs ranging from 24.6 to 93.4%. Thus, the authors concluded that the presence of IFs in CBCT examinations is relatively common

and characterized by significant variations in its frequency and nature, which may be attributed - at least partly - to differences in the individual populations sampled in the included studies.

Similarly to CBCT, a multicentre study in 15831 children head MSCT examinations - due to head trauma - showed IFs in 4% of them. Of these, 30% warranted immediate intervention or outpatient follow-up. It should be mentioned that the authors did not include findings consistent with inflammation in the paranasal sinuses and especially sinusitis findings, considering that these findings are particularly common in the paediatric and adolescent population [5].

Regarding the clinical significance of our findings, they are detailed in Table 3, and their frequencies and relative frequencies in Tables 4 and 5. Existing research suggests that although IFs of high clinical significance on CBCT are relatively rare [16], their existence and overall impact, in terms of requiring follow-up and/or interventions, warrants further investigation [15]. It is worth noting that dealing with an IF, unrelated to the reason of referral, is a controversial issue that implicates the core of medicine, law, and bioethics [22-25].

On one hand, patients have the inalienable “right to know” and in this sense, the health care provider must inform the patient about any finding of an examination method that concerns him, providing him with the full information he is entitled to [26]. Thus, dental radiologists should inform patients, despite any adverse consequences that may arise, as ultimately the patient is solely responsible for making any decision, and this autonomy should be respected [25,26]. A common paradigm of such a case is the identification of radiopacities compatible with the presence of calcifications within the carotid lumen either intra- or extra-cranially (Figure 2). As the presence of carotid plaque, when assessed, may be associated with an increased risk of stroke and coronary heart disease-related events, typically independent of other major cardiovascular risk factors [27]. Similarly, the radiographic differential diagnosis of an enlarged

*sella turcica* (Figure 3) includes several pathologic conditions, most commonly, a primary intrasellar pituitary tumour [28].

On the other hand, the abundance of medical information may eventually not benefit the patient, and there are literature recommendations indicative of a more “discreet” management of IFs with respect to patient information [2]. More specifically, benign, and insignificant IFs (e.g. tonsiloliths, etc.) might not be mentioned, since such unnecessary and superfluous knowledge may finally harm the patient in terms of increased anxiety and financial cost, leading to overdiagnosis and overtreatment [29,30].

Along the same lines as above, we only emphasize that the soft tissue pathology on osseous borders, airway asymmetry, enlarged sella and carotid artery calcification(s) found in our study; are IFs of high potential clinical significance, with extracranial calcified carotid artery atheroma being the most prevalent one (10.3%).

## CONCLUSIONS

A high prevalence of incidental findings is observed on cone-beam computed tomography examinations performed for preoperative evaluation for implant placement (99.5% if anatomical variants included). Their vast majority were of minor significance, not requiring further examination or referral. Although the number of incidental findings that require immediate attention is relatively low, there is a considerable number of cases that need periodic evaluation. It is crucial that clinicians interpret the total volume obtained in cone-beam computed tomography examinations and report when in doubt.

## ACKNOWLEDGMENTS AND DISCLOSURE STATEMENTS

The authors report no conflicts of interest related to this study.

## REFERENCES

1. Suomalainen A, Pakbaznejad Esmaceli E, Robinson S. Dentomaxillofacial imaging with panoramic views and cone beam CT. *Insights Imaging*. 2015 Feb;6(1):1-16. [Medline: [25575868](#)] [PMC free article: [4330237](#)]
2. Çağlayan F, Tozoğlu U. Incidental findings in the maxillofacial region detected by cone beam CT. *Diagn Interv Radiol*. 2012 Mar-Apr;18(2):159-63. [Medline: [21960135](#)] [doi: [10.4261/1305-3825.DIR.4341-11.2](#)]
3. Beigelman-Aubry C, Hill C, Grenier PA. Management of an incidentally discovered pulmonary nodule. *Eur Radiol*. 2007 Feb;17(2):449-66. [Medline: [17021707](#)] [doi: [10.1007/s00330-006-0399-7](#)]
4. Lumbreras B, Donat L, Hernández-Aguado I. Incidental findings in imaging diagnostic tests: a systematic review. *Br J Radiol*. 2010 Apr;83(988):276-89. [Medline: [20335439](#)] [PMC free article: [3473456](#)] [doi: [10.1259/bjr/98067945](#)]

5. Rogers AJ, Maher CO, Schunk JE, Quayle K, Jacobs E, Lichenstein R, Powell E, Miskin M, Dayan P, Holmes JF, Kuppermann N; Pediatric Emergency Care Applied Research Network. Incidental findings in children with blunt head trauma evaluated with cranial CT scans. *Pediatrics*. 2013 Aug;132(2):e356-63. [Medline: [23878053](#)] [doi: [10.1542/peds.2013-0299](#)]
6. Miles DA. with Cone-beam Volumetric Imaging - Report of Findings in 381 Cases. *US Dentistry*. 2006 Sept; 1(1): 39-42.
7. Cha JY, Mah J, Sinclair P. Incidental findings in the maxillofacial area with 3-dimensional cone-beam imaging. *Am J Orthod Dentofacial Orthop*. 2007 Jul;132(1):7-14. [Medline: [17628245](#)] [doi: [10.1016/j.ajodo.2005.08.041](#)]
8. Price JB, Thaw KL, Tyndall DA, Ludlow JB, Padilla RJ. Incidental findings from cone beam computed tomography of the maxillofacial region: a descriptive retrospective study. *Clin Oral Implants Res*. 2012 Nov;23(11):1261-8. [Medline: [22092929](#)] [doi: [10.1111/j.1600-0501.2011.02299.x](#)]
9. Pliska B, DeRoche M, Larson BE. Incidence of significant findings on CBCT scans of an orthodontic patient population. *Northwest Dent*. 2011 Mar-Apr;90(2):12-6. [Medline: [21667587](#)]
10. Pette GA, Norkin FJ, Ganeles J, Hardigan P, Lask E, Zfaz S, Parker W. Incidental findings from a retrospective study of 318 cone beam computed tomography consultation reports. *Int J Oral Maxillofac Implants*. 2012 May-Jun;27(3): 595-603. [Medline: [22616053](#)]
11. Allareddy V, Vincent SD, Hellstein JW, Qian F, Smoker WR, Ruprecht A. Incidental findings on cone beam computed tomography images. *Int J Dent*. 2012;2012:871532. [Medline: [23304148](#)] [PMC free article: [3523569](#)] [doi: [10.1155/2012/871532](#)]
12. Balshi TJ, Wolfinger GJ, Yang J, Wulc DA, Balshi SF. Prevalence of Non Dental Pathology in Cone Beam Computed Tomography Studies for Dental Implants. *JIACD*. 2013; 5(3):21-26. [URL: <https://dentalimplants-usa.com/wp-content/uploads/2018/03/prevalenceofnondentalpath2013.pdf>]
13. Rheem S, Nielsen IL, Oberoi S. Incidental findings in the maxillofacial region identified on cone-beam computed tomography scans. *Journal of Orthodontic Research*. 2013 Mar; 1(1): 33-9. [doi: [10.4103/2321-3825.112254](#)]
14. Edwards R, Alsufyani N, Heo G, Flores-Mir C. The frequency and nature of incidental findings in large-field cone beam computed tomography scans of an orthodontic sample. *Prog Orthod*. 2014 Jun 11;15(1):37. [Medline: [25033888](#)] [PMC free article: [4884029](#)] [doi: [10.1186/s40510-014-0037-x](#)]
15. Dođramacı EJ, Rossi-Fedele G, McDonald F. Clinical importance of incidental findings reported on small-volume dental cone beam computed tomography scans focused on impacted maxillary canine teeth. *Oral Surg Oral Med Oral Pathol Oral Radiol*. 2014 Dec;118(6):e205-9. [Medline: [25457895](#)] [doi: [10.1016/j.oooo.2014.09.006](#)]
16. Drage N, Rogers S, Greenall C, Playle R. Incidental findings on cone beam computed tomography in orthodontic patients. *J Orthod*. 2013 Mar;40(1):29-37. [Medline: [23524545](#)] [doi: [10.1179/1465313312Y.0000000027](#)]
17. Kuijpers MAR, Pazera A, Admiraal RJ, Bergé SJ, Vissink A, Pazera P. Incidental findings on cone beam computed tomography scans in cleft lip and palate patients. *Clin Oral Investig*. 2014 May;18(4):1237-1244. [Medline: [23979354](#)] [doi: [10.1007/s00784-013-1095-z](#)]
18. Lopes IA, Tucunduva RM, Handem RH, Capelozza AL. Study of the frequency and location of incidental findings of the maxillofacial region in different fields of view in CBCT scans. *Dentomaxillofac Radiol*. 2017 Jan;46(1): 20160215. [Medline: [27604390](#)] [PMC free article: [5595051](#)] [doi: [10.1259/dmfr.20160215](#)]
19. Crockett B, Broome A, Tawil P, Tyndall D. Incidental Findings On CBCT By Field Of View And Presence Or Absence On 2D Images. *Oral Surg Oral Med Oral Pathol Oral Radiol*. 2021 Sep;132(3): e106. [doi: [10.1016/j.oooo.2021.04.008](#)]
20. Dief S, Veitz-Keenan A, Amintavakoli N, McGowan R. A systematic review on incidental findings in cone beam computed tomography (CBCT) scans. *Dentomaxillofac Radiol*. 2019 Oct;48(7):20180396. [Medline: [31216179](#)] [PMC free article: [6775789](#)] [doi: [10.1259/dmfr.20180396](#)]
21. Edwards R, Altalibi M, Flores-Mir C. The frequency and nature of incidental findings in cone-beam computed tomographic scans of the head and neck region: a systematic review. *J Am Dent Assoc*. 2013 Feb;144(2):161-70. [Medline: [23372132](#)] [doi: [10.14219/jada.archive.2013.0095](#)]
22. Tovino SA. Incidental findings: a common law approach. *Account Res*. 2008 Oct-Dec;15(4):242-61. [Medline: [18972265](#)] [doi: [10.1080/08989620802388705](#)]
23. Illes J. 'Pandora's box' of incidental findings in brain imaging research. *Nat Clin Pract Neurol*. 2006 Feb;2(2):60-1. [Medline: [16932523](#)] [doi: [10.1038/ncpneuro0119](#)]
24. Illes J, Kirschen MP, Edwards E, Stanford LR, Bandettini P, Cho MK, Ford PJ, Glover GH, Kulynych J, Macklin R, Michael DB, Wolf SM; Working Group on Incidental Findings in Brain Imaging Research. Ethics. Incidental findings in brain imaging research. *Science*. 2006 Feb 10;311(5762):783-4. [Medline: [16469905](#)] [PMC free article: [1524853](#)] [doi: [10.1126/science.1124665](#)]
25. American Medical Association Council on Ethical and Judicial Affairs. Section 8.082. Withholding Information from Patients. In: Code of Medical Ethics of the American Medical Association, 2010-2011. Chicago, IL:American Medical Association; 2010: 269-70. [doi: [10.1001/virtualmentor.2011.13.12.coet1-1112](#)]
26. Brown SD. Professional norms regarding how radiologists handle incidental findings. *J Am Coll Radiol*. 2013 Apr;10(4):253-7. [Medline: [23545084](#)] [doi: [10.1016/j.jacr.2012.10.003](#)]



27. Garg PK, Bhatia HS, Allen TS, Grainger T, Pouncey AL, Dichek D, Virmani R, Golledge J, Allison MA, Powell JT. Assessment of Subclinical Atherosclerosis in Asymptomatic People In Vivo: Measurements Suitable for Biomarker and Mendelian Randomization Studies. *Arterioscler Thromb Vasc Biol.* 2024 Jan;44(1):24-47. [Medline: [38150519](#)] [doi: [10.1161/ATVBAHA.123.320138](#)]
28. Chang HP, Tseng YC, Chou TM. An enlarged sella turcica on cephalometric radiograph. *Dentomaxillofac Radiol.* 2005 Sep;34(5):308-12. [Medline: [16120882](#)] [doi: [10.1259/dmfr/27388408](#)]
29. Lichtenfeld L. Overdiagnosed: Making people sick in the pursuit of health. *J Clin Invest.* 2011 Aug 1;121(8):2954. [PMC free article: [3148742](#)] [doi: [10.1172/JCI57171](#)]
30. Volk ML, Ubel PA. Better off not knowing: improving clinical care by limiting physician access to unsolicited diagnostic information. *Arch Intern Med.* 2011 Mar 28;171(6):487-8. [Medline: [21444838](#)] [PMC free article: [3168567](#)] [doi: [10.1001/archinternmed.2011.63](#)]

**To cite this article:**

Theodoridis C, Damaskos S, Angelopoulos C.

Frequency and Clinical Significance of Incidental Findings on CBCT Imaging: a Retrospective Analysis of Full-Volume Scans  
*J Oral Maxillofac Res* 2024;15(1):e5

URL: <http://www.ejomr.org/JOMR/archives/2024/1/e5/v15n1e5.pdf>

doi: [10.5037/jomr.2024.15105](#)

**Copyright** © Theodoridis C, Damaskos S, Angelopoulos C. Published in the JOURNAL OF ORAL & MAXILLOFACIAL RESEARCH (<http://www.ejomr.org>), 31 March 2024.

This is an open-access article, first published in the JOURNAL OF ORAL & MAXILLOFACIAL RESEARCH, distributed under the terms of the [Creative Commons Attribution-Noncommercial-No Derivative Works 3.0 Unported License](#), which permits unrestricted non-commercial use, distribution, and reproduction in any medium, provided the original work and is properly cited. The copyright, license information and link to the original publication on (<http://www.ejomr.org>) must be included.