

Mastication Influences Human Brain Anatomy

Lucia Lopez-Chaichio¹, Pablo Galindo-Moreno², Miguel Padial-Molina², Lourdes Gutierrez-Garrido³, Roque Rodriguez-Alvarez⁴, Francisco O'Valle⁵, Andres Catena⁶

¹Private practice, Jaen, Spain. Formerly PhD Program in Clinical Medicine and Public Health, University of Granada, Granada, Spain.

²Department of Oral Surgery and Implant Dentistry, School of Dentistry, and Instituto Biosanitario de Granada (Ibs.GRANADA), University of Granada, Granada, Spain.

³Private practice, Granada, Spain. Formerly PhD Program in Clinical Medicine and Public Health, University of Granada, Granada, Spain.

⁴PhD Program in Clinical Medicine and Public Health, University of Granada, Granada, Spain.

⁵Department of Pathology and IBIMER, School of Medicine, and Instituto Biosanitario de Granada (Ibs.GRANADA), University of Granada, Granada, Spain.

⁶Department of Experimental Psychology, School of Psychology, University of Granada, Granada, Spain.

Corresponding Author:

Pablo Galindo-Moreno
School of Dentistry
University of Granada
Campus Universitario de Cartuja, s/n 18071, Granada
Spain
Phone: (+34) 958 249032
E-mail: pgalindo@ugr.es

ABSTRACT

Objectives: The purpose of this observational clinical study was to evaluate the relationship between brain anatomical and volumetric changes in white matter, grey matter, and cerebral cortex thickness with the number of functional occlusal pairs present in the mouth.

Material and Methods: The number of functional occlusal pairs in 70 patients was counted and non-invasive brain analysis was performed using magnetic resonance imaging. The volume of grey matter, white matter, and thickness of the cortex in different areas of the brain were determined by SPM12 and CAT12 software. Multiple regression model corrected for multiple comparisons using FDR and Spearman correlation coefficient were calculated for statistical comparison.

Results: A total of 70 (39 male, 31 female) were analysed, with an average number of occlusal pairs of 10.21 (3.99). According to the Spearman correlation coefficient, a lower number of occlusal pairs was related to a reduction in white matter (right external capsule and posterior limb of the internal capsule), a reduction in grey matter (right temporal superior and medial gyrus and left *cerebellum crus 1*) and a reduction in thickness of the cerebral cortex (rostral anterior cingulate cortex of the right hemisphere and areas in the right and left hemisphere, especially in the frontal cortex).

Conclusions: The number of occlusal pairs is related to the volume of white matter, grey matter, and thickness of the cerebral cortex in areas of the brain that are directly involved in the onset and progression of Alzheimer's disease and other dementias.

Keywords: dental occlusion; cognitive decline; Alzheimer disease; gray matter; white matter.

Accepted for publication: 31 December 2024

To cite this article:

Lopez-Chaichio L, Galindo-Moreno P, Padial-Molina M, Gutierrez-Garrido L, Rodriguez-Alvarez R, O'Valle F, Catena A.

Mastication Influences Human Brain Anatomy

J Oral Maxillofac Res 2024;15(4):e4

URL: <http://www.ejomr.org/JOMR/archives/2024/4/e4/v15n4e4.pdf>

doi: [10.5037/jomr.2024.15404](https://doi.org/10.5037/jomr.2024.15404)

INTRODUCTION

The world's population is aging. This aging has led to an increase in the incidence of neurodegenerative diseases. As a consequence, neurological disorders are the leading cause of disability-adjusted life-years [1]. This will not decrease in the near future; in turn, it is expected that the number of patients with dementia triple in the next 30 years [2]. The leading cause of dementia is Alzheimer's disease. Classically, the disease has been characterized by the accumulation of intra and extracellular peptides such as amyloid- β protein or neurofibrillary tangles [3]. The accumulation of such peptides generates environmental toxicity, neuronal death, and a reduction in synapses. As a result, there is an alteration in cognitive functions and, at the end, the impossibility of performing daily tasks autonomously. In Alzheimer's there is also an alteration in the white matter [4], grey matter [5] and the thickness of the cerebral cortex [6]. Despite the fact that aging is the main and inevitable risk factor for the appearance of this disease [7], multiple situations can act as risk or protective factors in the progression of its onset and progression [8]. Physical, cultural, or social activities have been well determined as protective factors.

Because of the absence of effective strategies in the treatment of Alzheimer's, there is an increasing interest in the study of those and other factors to prevent the progression of Alzheimer's disease. Among them, the role of oral health as a protective factor in the advancement of neurodegenerative diseases has been evaluated [9]. In summary, there is enough evidence from animal studies concluding that occlusal alterations or absence of molars cause a decline in cognitive functions through a direct reduction of stimuli, an alteration of the hypothalamic-pituitary-adrenal axis, an increase in the inflammatory response and an alteration of the cerebral brain-derived neurotrophic factor (BDNF) and its receptor, tropomyosin receptor kinase B (TrkB). Altogether, these situations lead to a reduction in adult neurogenesis, a decrease in synapses and an increase in neuronal apoptosis [10-12]. In humans, evidence from several observational [13] and epidemiological studies [14] also confirms the association between both oral health and cognitive functions. However, the pathway for such association is not well known yet. Particularly, the classical periodontal pathway suggested an association mediated by the inflammatory status. This hypothesis is being questioned [15]. In turn, occlusal function itself is gaining more and more attention. Occlusal function

is determined by many factors. Indirectly, the number of missing teeth is classically used as cut-off. More interestingly, though, is the number of functional occlusal pairs, either prosthetically rehabilitated or not. Therefore, because of the lack of previous studies, the aim of this observational clinical study was to determine the importance of occlusal function measured through functional occlusal pairs present in the mouth and its relationship with the cerebral anatomical state, particularly in the form of changes in white and grey matter and thickness of the cerebral cortex.

MATERIAL AND METHODS

Participants

A total of 80 participants were consecutively enrolled from November 2016 to January 2020 in this cross-sectional study from those attending the Department of Oral Surgery and Implant Dentistry, University of Granada (Granada, Spain), either for third molar removal or for rehabilitation of missing teeth by dental implants. To be included in the study, the only condition was either to have at least the 28 functional teeth in the mouth (excluding third molars) or, in the case of having missing teeth (excluding third molars), to have not worn a prosthetic rehabilitation for at least 1 year since tooth extraction. Patients were excluded if they were taking any kind of psychoactive drug, central nervous system depressor or could not be subjected to the magnetic resonance imaging (MRI) techniques because of presence of metallic objects in the body (stents, for example) or any other medical condition that contraindicated the MRI study.

Participants were informed of their rights, signed an informed consent form, and were treated in accordance with the Helsinki declaration. This research was approved by the Ethics Committee on Human Research of the University of Granada (no. CEIH: 905). The manuscript has been prepared following the STROBE guidelines for observational studies.

MRI scanning and analysis

MRI were obtained with a Siemens Trio 3T scanner equipped with a 32-channel head coil (Siemens Healthineers; Erlangen, Germany) and located at the Mind, Brain and Behaviour Research Centre, University of Granada. Subject's head movements were minimized using a head restraint system and foam padding around the subject's head.

T1 weighted structural images were obtained using a magnetization-prepared rapid gradient-echo (MPRAGE) pulse sequence (TR = 1900 ms; TE = 2.52 ms; flip angle = 9°). For each volume, 176 slices of 1 mm thickness were acquired with the following parameters: voxel size = 1 × 1 × 1 mm³; FOV = 256 × 256 mm²; matrix size = 256 × 256.

The Computational Anatomy Toolbox (CAT12) [16] was used to perform the voxel based morphometry and the thickness estimation of cortical grey matter, with the default parameters. CAT12 is the current version of the CAT software and runs in MATLAB (MathWorks) or as a standalone version with no need for a MATLAB license. Basically, CAT preprocessing consists on the following stages: denoising (using spatial-adaptive non-local means and classical Markov random field), interpolation (to improve image quality), affine preprocessing, local adaptive segmentation (using a local intensity transformation of all tissue classes to reduce differences in grey matter intensities in different part of the brain), adaptive maximum a posteriori technique (AMAP, being adaptive so that local variation of the parameters are modelled as slowly varying spatial functions), partial volume segmentation (that include grey matter, white matter, cerebrospinal fluid and two mixed tissue classes: grey-white matter and grey-cerebrospinal fluid), skull stripping and clean-up, an spatial normalization to the Montreal Neurological Institute (MNI) template (<https://neuroconductor.org/help/mni/index.html>). For the estimation of cortical thickness, CAT uses a tissue segmentation to estimate the white matter distance, then projects the local maxima to other grey matter voxels by using a neighbour relationship described by the white matter distance.

Procedure

Between November 2016 and January 2020, each participant was firstly evaluated at the School of Dentistry, University of Granada. A full-oral and dental exam was conducted. Data on number of teeth and occlusal pairs were collected. In addition, sociodemographic data were also acquired, including age, gender, laterality, educational level, and tobacco and alcohol consumption. Then, participants were referred to the Mind, Brain and Behaviour Research Centre, University of Granada, for the MRI scan. The scanning session extended for about half an hour.

Statistical analysis

Statistical Parametric Mapping software package

version 12 (SPM12) software (Wellcome Department of Imaging Neuroscience; University College, London, UK) and CAT12 were used for the analysis of the voxel-based volumetric data and the region-of-interest analysis of cortical thickness, respectively. In both analyses, a multiple regression model was used, in which the predictor of interest was the number of occlusal pairs remaining in mouth and the variables of no interest were age, gender, occupation and educational level. For the volumetric data, the total intracranial volume was used as an additional covariate of no interest. For the cortical thickness we used the Desikan-Killiany Atlas (<https://identifiers.org/neurovault.image:23262>) as implemented in CAT12. A significance level of 0.05 corrected for multiple comparisons using false discovery rate (FDR) at the cluster level was used for all the analyses. The Spearman correlation coefficient (r) was used to assess the association between the number of occlusal pairs and the remaining predictors of no interest.

Data availability

The data that support the findings of this study are available from the corresponding author upon reasonable request.

RESULTS

Of all the participants who signed the informed consent, 70 (39 male, 31 female) were able to pass the magnetic resonance stage, while the remaining 10 participants were not amenable for the MRI stage because of several health conditions. Average age was 57.46 years ([SD 9.79]; min 38; max 75). All participants were right-handed. By education level, 35% had a primary level or less, 21% had attended secondary studies, 15% high-school and 29% graduated at university. 54% of the participants had never smoked and 40% had never consumed alcohol (Table 1).

The average number of occlusal pairs remaining in the mouth was 10.21 ([SD 3.99]; min 0; max 15). There was no association between number of occlusal pairs and age (r = -0.089, P = 0.46). There was a tendency for women to have more occlusal pairs than men (r = 0.27, P = 0.024, averages of 9.3 and 11.4, respectively for men and women). Finally, it was determined that the higher the level of education of the subjects, the higher the number of occlusal pairs (r = 0.28, P = 0.019).

The analysis of the volumetric data yielded effect of

the number of occlusal pairs both in grey and white matter. Regarding grey matter, more volume was observed in an area of the right temporal superior and medial gyrus and in the left *cerebellum crus 1* when more occlusal pairs were present (Figure 1, Table 2). Regarding white matter, effects were observed for the number of occlusal pairs in the right external capsule and the right posterior limb of the internal capsule in the same direction: the higher the number of occlusal pairs, the higher the volume of the indicated areas (Figure 2, Table 2). The analysis of the thickness of the cerebral cortex yielded an effect of the number of remaining occlusal pairs on the rostral anterior cingulate cortex of the right hemisphere, when corrected for multiple comparisons (Figure 3A). A less stringent criterion not correcting for multiple comparisons was also adopted to assess potential candidate areas correlating with the number of occlusal pairs. In this case, areas in the left and right hemisphere, especially in the frontal cortex were reduced in thickness of their cortex when the number of occlusal pairs was reduced (Figure 3B, Table 3).

Table 1. Demographic and baseline data of patients included in the study

Age	
Mean; min; max	57.46; 38; 75
Gender, n (%)	
Male	39 (56%)
Female	31 (44%)
Tobacco consumption, n (%)	
Yes	32 (46%)
No	38 (54%)
Alcohol consumption, n (%)	
Yes	42 (60%)
No	28 (40%)
Education level, n (%)	
Primary	25 (35%)
Secondary	15 (21%)
High school	10 (15%)
University	20 (29%)
Average number of occlusal pairs	
Mean (SD); min; max	10.21 (3.99); 0; 15

SD = standard deviation.

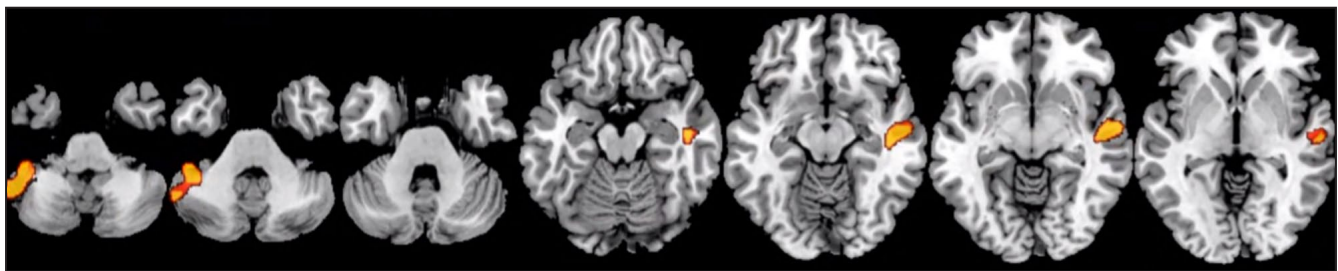


Figure 1. The two significant cluster of grey matter positively associated to the number of occlusal pairs.

Table 2. Areas of grey and white matter which volume is significantly associated with the number of occlusal pairs in the mouth

	Hemisphere	Area	k	Student's t-test	X	Y	Z
Grey matter	Right	Temporal superior/mid	766	4.46	53	-14	-5
	Left	<i>Cerebellum crus 1</i>	695	4.26	-42	-41	-41
White matter	Right	External capsule/posterior limb of internal capsule	475	4.38	24	-14	8

k = size in voxels; X, Y, Z = Montreal Neurological Institute (MNI) coordinates of the peak of the cluster.

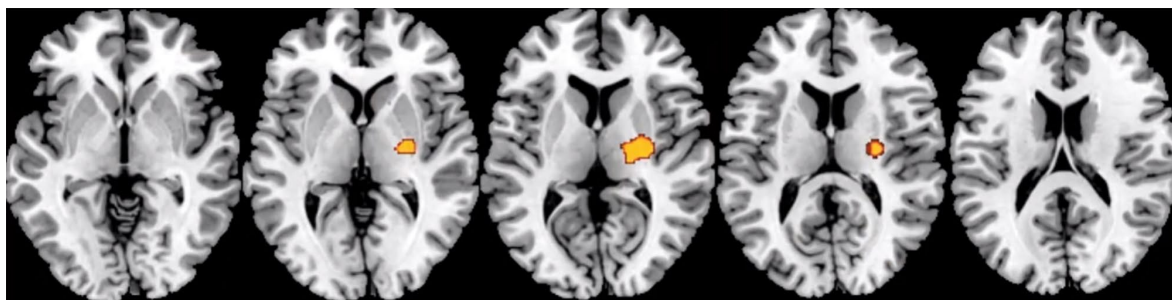


Figure 2. The cluster of white matter positively associated to the number of occlusal pairs.

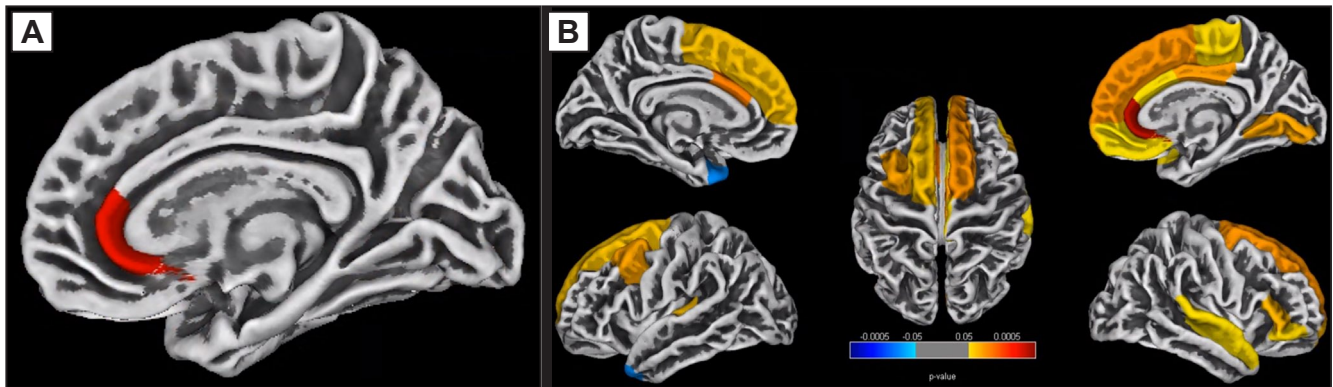


Figure 3. A = the rostral anterior cingulate cortex of the right hemisphere positively associated to the number of occlusal pairs in the mouth. B = areas of cerebral cortex thickness associated to the number of occlusal pairs in the mouth without correcting for multiple comparisons.

Table 3. Areas of the cerebral cortex which thickness is significantly associated with the number of occlusal pairs in the mouth

Hemisphere	P-value ^a	k	Overlap	Region	Association
Left	0.005	17354	70%	Superior frontal	Positive
			22%	Caudal middle frontal	Positive
			8%	Caudal anterior cingulate	Positive
	0.01	839	100%	Temporal pole	Negative
Right	< 0.001	24532	48%	Superior frontal	Positive
			16%	Paracentral	Positive
			12%	Posterior cingulate	Positive
			11%	Medial orbital	Positive
			7%	Caudal anterior cingulate	Positive
			4%	Rostral anterior cingulate	Positive
	0.05	6868	100%	Superior temporal	Positive
	0.02	3886	100%	Lingual	Positive
0.02	3326	72%	Pars triangularis	Positive	
		28%	Pars orbitalis	Positive	

^aSpearman correlation coefficient.
k = size of the cluster.

DISCUSSION

The current study uses non-invasive MRI techniques combined with the objective analysis of the patient’s occlusal status. This combination allows us to obtain objective information that relates both variables. In this study, we report a reduction in white matter, grey matter, and cortical thickness in patients with fewer occlusal dental pairs, independently of the patient’s age. We observed changes in the white matter in the right external capsule and posterior limb of the internal capsule. The changes observed in the grey matter involve especially the right temporal superior and medial gyrus and left *cerebellum crus 1*. Regarding the cerebral cortex, we found a reduction of its the thickness in the rostral anterior cingulate cortex of the right hemisphere,

and several areas in the right and left hemisphere, especially in the frontal cortex. To our knowledge, no study has been done analysing such changes until now.

Our findings are of paramount importance. The areas of the brain that we found to be modified in association to the number of occlusal pairs in the mouth are also related to the progression of several diseases that course with dementia. Grey matter of the superior hemisphere and middle temporal gyrus have been observed to be reduced in Alzheimer’s disease [8]. They are associated with short-term memory, speech comprehension and attention [17]. White matter changes are also associated to cognitive decline, Alzheimer and dementia [4]. Particularly, the reduction of white matter in the external capsule is related to alterations in executive functions [4] and a reduction in cholinergic fibres [18].

Together, these changes contribute to explain some of the executive dysfunctions and alterations in cognitive functions that are seen in Alzheimer's disease. Even more, structural changes in the brain white matter can be observed decades before the onset of clinical symptoms of Alzheimer's disease [6]. This white matter loss precedes the loss of grey matter [19].

The rostral anterior cingulate cortex has been related to the emotional aspects of frontotemporal dementia [20], fear [21] and several cognitive functions as memory [22]; or as suggested recently, this area constitutes a connectional hub in emotion and cognitive control [23]. Thinner rostral anterior cingulate cortex has been previously observed in a group with amyloid- β , compared to the control group of the same age but without amyloid- β [24]. Consequently, there is a negative association between rostral anterior cingulate thickness and overall cognitive function [25].

In the current study, and for the first time in the literature, we have found the described structures to be negatively affected by loss of teeth, particularly the reduction of functional pairs of occluding teeth, i.e., occlusal pairs. This is masticatory deficiency negatively affects important areas of the brain related to cognition and particularly affected in Alzheimer's disease. These connections between masticatory function and cognitive decline have been reviewed by our group elsewhere [9]. Briefly, the possible connection has been explained by several reasons. For example, there is a direct activation of brain areas and increase in cerebral blood flow to those areas during mastication. Thus, there is greater angiogenesis and better neurotrophic support [26-28]. In addition, there is an increase in trigeminal sensory inputs towards the *locus coeruleus* that leads to a modulation of neuroinflammation and the noradrenergic system, improving neurotrophic support and favouring the phagocytosis of beta amyloid plaques [29-32]. There is also an increase in the release of myokines from the masticatory muscles such as irisin, which lead to an increase in hippocampal BDNF, improving neuronal plasticity, hippocampal volume, neurotrophic support and the non-amyloidogenic pathway of the amyloid precursor protein [33-35].

Most of these pathways described in animal models have only been suggested in humans by observational and cross-sectional studies of the effects. In fact, our own group has recently conducted a study of large databases from several national health surveys for a total of 102,291 individuals. We found that edentulism is among the factors associated to cognitive, memory or concentrating issues with the highest odds ratio (OR). In some cases, this OR was even higher than

that of other commonly accepted confounders such as age, education level or socio-economic status [14]. In fact, when the model was adjusted for such confounders, the OR of edentulism and cognitive problems was still high at 2.38. Moreover, we also tested whether people under age 45 showed an increased probability of having memory/confusion problems. This analysis showed an OR of 1.88. Thus, we may suggest that the association between masticatory and cognitive functions is independent of such other factors, including age. Moreover, as opposed to other previous studies that set 9 teeth as the limit to consider edentulism, the association we found had a cut-off value of 20 teeth, while 28 is considered as full dentition. This indicates that cognitive function might be affected when very few teeth are lost. Similar findings have also been recently reported, with 11 pairs of masticatory pairs as the limit for significant association [36]. Interestingly, compared to other types of teeth, loss of molars shows the highest OR in the association with cognitive issues: 1.32 [14]. Recent findings confirm the importance of occlusal function with molars in the association with cognitive status [37]. Molars are the main teeth responsible for mastication and are correlated with muscle function [38], and highly affect the activation of specific areas of the brain [27]. Additionally, the loss of molars is associated with neuronal apoptosis in the hippocampus through the activation of the p38MAPK-NF κ B-caspase 3 signalling pathway [39]. Thus, masticatory function itself, with either natural dentition or occlusal rehabilitation, as also suggested in other studies, could be the responsible for the association, rather than just the number of teeth [3]. It is also important to consider that patient satisfaction and quality of life increases tremendously with just single retention of the prosthesis by dental implants, regardless of the number of them [43]. In any case, some types of prosthesis, particularly implant-supported fixed dentures, show better induction of functional neuroplasticity in patients undergoing denture rehabilitation [44]. Moreover, this association showed a gradient effect: the lower the number of teeth, the greater the risk of exhibiting cognitive decline; in addition, the sooner tooth loss happens, the earlier cognitive impairment appears [14].

Thus, oral health is demonstrated to be a potent effector in healthy cognitive ageing. As we demonstrate in this study, there is a relationship between the number of dental occlusal pairs, and, therefore, masticatory function, with brain anatomical features that are directly involved in cognition and development of Alzheimer's disease. Consequently, in the absence of effective therapies to stop Alzheimer's

disease, and in addition to the control of other risk factors, we must propose oral health, prevention of tooth loss and, ultimately, occlusal restoration, if needed, as a tool to fight neurodegenerative diseases.

The current study analysed only the number of occlusal pairs as a determinant of masticatory function. Masticatory function, however, is more complex than just number of teeth. Among others, mastication has important key characteristics:

1. Involves muscular activity and proprioception;
2. Can be automatic or voluntary;
3. It is influenced by the type of restoration, pathology or status of the teeth themselves and the surrounding structures (i.e., periodontal ligament);
4. Can be affected by parafunctions such as bruxism, highly dependent on stress and anxiety.

Cognitive decline and Alzheimer are also more than just anatomical changes in the brain. However, altogether, the information presented is objective and potentially justifies pathways of association between the two conditions. Thus, it is necessary to deepen the understanding of both entities and their relation by determining the interaction pathway through intervention studies, anatomo-pathological analyses, and biological investigations. This combination will allow us to establish effective strategies to help slow down some devastating cognitive diseases.

CONCLUSIONS

In order to contribute to the search for effective

strategies in the fight against Alzheimer's disease and other dementias, a study was conducted in which non-invasive brain analysis was combined with the MRI technique and the objective evaluation of masticatory function based on the number of occlusal pairs of teeth.

The results of the present study revealed that a lower number of occlusal pairs is related to a reduction in white matter, gray matter, and the thickness of the cerebral cortex in brain anatomical areas directly involved in the onset or progression of Alzheimer's disease and other dementias.

ACKNOWLEDGMENTS AND DISCLOSURE STATEMENTS

The authors declare no conflict of interest, either directly or indirectly, in any of the products listed in the manuscript.

This investigation was partially supported by the University of Granada (M.P.-M., P.G.-M., L.L.-C., F.O. and A.C., Precompetitive Research Projects, 2016-P1-23, and PP2022.PP-01), Asisa Dental SA (P.G.-M., M.P.-M., F.O. and A.C., knowledge transfer agreement between the company and the Technology Transfer Office of the University of Granada #C-4188), and non-specific funding from Junta de Andalucía (F.O., CTS-138; A.C., CTS-176; M.P.-M. and P.G.-M., CTS-1028).

REFERENCES

1. GBD 2016 Neurology Collaborators. Global, regional, and national burden of neurological disorders, 1990-2016: a systematic analysis for the Global Burden of Disease Study 2016. *Lancet Neurol.* 2019 May;18(5):459-480. [Medline: [30879893](#)] [PMC free article: [PMC6459001](#)] [doi: [10.1016/S1474-4422\(18\)30499-X](#)]
2. GBD 2019 Dementia Forecasting Collaborators. Estimation of the global prevalence of dementia in 2019 and forecasted prevalence in 2050: an analysis for the Global Burden of Disease Study 2019. *Lancet Public Health.* 2022 Feb;7(2):e105-e125. [Medline: [34998485](#)] [PMC free article: [PMC8810394](#)] [doi: [10.1016/S2468-2667\(21\)00249-8](#)]
3. Canter RG, Penney J, Tsai LH. The road to restoring neural circuits for the treatment of Alzheimer's disease. *Nature.* 2016 Nov 10;539(7628):187-196. [Medline: [27830780](#)] [doi: [10.1038/nature20412](#)]
4. Nolze-Charron G, Dufort-Rouleau R, Houde JC, Dumont M, Castellano CA, Cunnane S, Lorrain D, Fülöp T, Descoteaux M, Bocti C. Tractography of the external capsule and cognition: A diffusion MRI study of cholinergic fibers. *Exp Gerontol.* 2020 Feb;130:110792. [Medline: [31778753](#)] [doi: [10.1016/j.exger.2019.110792](#)]
5. Wu Z, Peng Y, Hong M, Zhang Y. Gray Matter Deterioration Pattern During Alzheimer's Disease Progression: A Regions-of-Interest Based Surface Morphometry Study. *Front Aging Neurosci.* 2021 Feb 3;13:593898. [Medline: [33613265](#)] [PMC free article: [7886803](#)] [doi: [10.3389/fnagi.2021.593898](#)]
6. Hiscox LV, Johnson CL, McGarry MDJ, Marshall H, Ritchie CW, van Beek EJ, Roberts N, Starr JM. Mechanical property alterations across the cerebral cortex due to Alzheimer's disease. *Brain Commun.* 2020;2(1):fcz049. [Medline: [31998866](#)] [PMC free article: [6976617](#)] [doi: [10.1093/braincomms/fcz049](#)]
7. Mayeux R, Stern Y. Epidemiology of Alzheimer disease. *Cold Spring Harb Perspect Med.* 2012 Aug 1;2(8):a006239. [Medline: [22908189](#)] [PMC free article: [3405821](#)] [doi: [10.1101/cshperspect.a006239](#)]

8. Livingston G, Huntley J, Sommerlad A, Ames D, Ballard C, Banerjee S, Brayne C, Burns A, Cohen-Mansfield J, Cooper C, Costafreda SG, Dias A, Fox N, Gitlin LN, Howard R, Kales HC, Kivimäki M, Larson EB, Ogunniyi A, Orgeta V, Ritchie K, Rockwood K, Sampson EL, Samus Q, Schneider LS, Selbæk G, Teri L, Mukadam N. Dementia prevention, intervention, and care: 2020 report of the Lancet Commission. *Lancet*. 2020 Aug 8;396(10248):413-446. [Medline: [32738937](#)] [PMC free article: [PMC7392084](#)] [doi: [10.1016/S0140-6736\(20\)30367-6](#)]
9. Lopez-Chaichio L, Padiál-Molina M, O'Valle F, Gil-Montoya JA, Catena A, Galindo-Moreno P. Oral health and healthy chewing for healthy cognitive ageing: A comprehensive narrative review. *Gerodontology*. 2021 Jun;38(2):126-135. [Medline: [33179281](#)] [doi: [10.1111/ger.12510](#)]
10. Ono Y, Yamamoto T, Kubo KY, Onozuka M. Occlusion and brain function: mastication as a prevention of cognitive dysfunction. *J Oral Rehabil*. 2010 Aug;37(8):624-40. [Medline: [20236235](#)] [doi: [10.1111/j.1365-2842.2010.02079.x](#)]
11. Okihara H, Ito J, Kokai S, Ishida T, Hiranuma M, Kato C, Yabushita T, Ishida K, Ono T, Michikawa M. Liquid diet induces memory impairment accompanied by a decreased number of hippocampal neurons in mice. *J Neurosci Res*. 2014 Aug;92(8):1010-7. [Medline: [24687840](#)] [doi: [10.1002/jnr.23383](#)]
12. Fukushima-Nakayama Y, Ono T, Hayashi M, Inoue M, Wake H, Ono T, Nakashima T. Reduced Mastication Impairs Memory Function. *J Dent Res*. 2017 Aug;96(9):1058-1066. [Medline: [28621563](#)] [doi: [10.1177/0022034517708771](#)]
13. Fang WL, Jiang MJ, Gu BB, Wei YM, Fan SN, Liao W, Zheng YQ, Liao SW, Xiong Y, Li Y, Xiao SH, Liu J. Tooth loss as a risk factor for dementia: systematic review and meta-analysis of 21 observational studies. *BMC Psychiatry*. 2018 Oct 20;18(1):345. [Medline: [30342524](#)] [PMC free article: [6195976](#)] [doi: [10.1186/s12888-018-1927-0](#)]
14. Galindo-Moreno P, Lopez-Chaichio L, Padiál-Molina M, Avila-Ortiz G, O'Valle F, Ravida A, Catena A. The impact of tooth loss on cognitive function. *Clin Oral Investig*. 2022 Apr;26(4):3493-3500. [Medline: [34881401](#)] [PMC free article: [8979879](#)] [doi: [10.1007/s00784-021-04318-4](#)]
15. Gil Montoya JA, Barrios R, Sanchez-Lara I, Ramos P, Camero C, Fornieles F, Montes J, Santana S, Luna JD, Gonzalez-Moles MA. Systemic inflammatory impact of periodontitis on cognitive impairment. *Gerodontology*. 2020 Mar;37(1):11-18. [Medline: [31347730](#)] [doi: [10.1111/ger.12431](#)]
16. Gaser C, Dahnke R, Thompson PM, Kurth F, Luders E, The Alzheimer's Disease Neuroimaging Initiative. CAT: a computational anatomy toolbox for the analysis of structural MRI data. *Gigascience*. 2024 Jan 2;13:giae049. [Medline: [39102518](#)] [PMC free article: [11299546](#)] [doi: [10.1093/gigascience/giae049](#)]
17. Vander Ghinst M, Bourguignon M, Op de Beeck M, Wens V, Marty B, Hassid S, Choufani G, Jousmäki V, Hari R, Van Bogaert P, Goldman S, De Tiège X. Left Superior Temporal Gyrus Is Coupled to Attended Speech in a Cocktail-Party Auditory Scene. *J Neurosci*. 2016 Feb 3;36(5):1596-606. [Medline: [26843641](#)] [PMC free article: [6601992](#)] [doi: [10.1523/JNEUROSCI.1730-15.2016](#)]
18. Schmammann JD, Smith EE, Eichler FS, Filley CM. Cerebral white matter: neuroanatomy, clinical neurology, and neurobehavioral correlates. *Ann N Y Acad Sci*. 2008 Oct;1142:266-309. [Medline: [18990132](#)] [PMC free article: [3753195](#)] [doi: [10.1196/annals.1444.017](#)]
19. Mendez Colmenares A, Voss MW, Fanning J, Salerno EA, Gothe NP, Thomas ML, McAuley E, Kramer AF, Burzynska AZ. White matter plasticity in healthy older adults: The effects of aerobic exercise. *Neuroimage*. 2021 Oct 1;239:118305. [Medline: [34174392](#)] [doi: [10.1016/j.neuroimage.2021.118305](#)]
20. Mitchell E, Tavares TP, Palaniyappan L, Finger EC. Hoarding and obsessive-compulsive behaviours in frontotemporal dementia: Clinical and neuroanatomic associations. *Cortex*. 2019 Dec;121:443-453. [Medline: [31715541](#)] [doi: [10.1016/j.cortex.2019.09.012](#)]
21. de Lima MAX, Baldo MVC, Oliveira FA, Canteras NS. The anterior cingulate cortex and its role in controlling contextual fear memory to predatory threats. *Elife*. 2022 Jan 5;11:e67007. [Medline: [34984975](#)] [PMC free article: [8730726](#)] [doi: [10.7554/eLife.67007](#)]
22. Gefen T, Papastefan ST, Rezvanian A, Bigio EH, Weintraub S, Rogalski E, Mesulam MM, Geula C. Von Economo neurons of the anterior cingulate across the lifespan and in Alzheimer's disease. *Cortex*. 2018 Feb;99:69-77. [Medline: [29175073](#)] [PMC free article: [5801202](#)] [doi: [10.1016/j.cortex.2017.10.015](#)]
23. Tang W, Jbabdi S, Zhu Z, Cottaar M, Grisot G, Lehman JF, Yendiki A, Haber SN. A connectional hub in the rostral anterior cingulate cortex links areas of emotion and cognitive control. *Elife*. 2019 Jun 19;8:e43761. [Medline: [31215864](#)] [PMC free article: [6624020](#)] [doi: [10.7554/eLife.43761](#)]
24. Pelkmans W, Legdeur N, ten Kate M, Yaqub MM, Van Berckel BNM, Visser PJ, Tijms BM. Amyloid- β is associated with thinner cortex in cognitively normal oldest-old individuals. *Alzheimers Dement*. 2019 Jul;15(7):04-5. [doi: [10.1016/j.jalz.2019.06.3431](#)]
25. Hays CC, Zlatař ZZ, Meloy MJ, Osuna J, Liu TT, Galasko DR, Wierenga CE. Anterior Cingulate Structure and Perfusion is Associated with Cerebrospinal Fluid Tau among Cognitively Normal Older Adult APOE ϵ 4 Carriers. *J Alzheimers Dis*. 2020;73(1):87-101. [Medline: [31743999](#)] [PMC free article: [7310575](#)] [doi: [10.3233/JAD-190504](#)]
26. Quintero A, Ichescó E, Schutt R, Myers C, Peltier S, Gerstner GE. Functional connectivity of human chewing: an fMRI study. *J Dent Res*. 2013 Mar;92(3):272-8. [Medline: [23355525](#)] [PMC free article: [3576996](#)] [doi: [10.1177/0022034512472681](#)]

27. Shoi K, Fueki K, Usui N, Taira M, Wakabayashi N. Influence of posterior dental arch length on brain activity during chewing in patients with mandibular distal extension removable partial dentures. *J Oral Rehabil.* 2014 Jul;41(7):486-95. [Medline: [24697794](#)] [doi: [10.1111/joor.12169](#)]
28. Lotze M, Domin M, Kordass B. Symmetry of fMRI activation in the primary sensorimotor cortex during unilateral chewing. *Clin Oral Investig.* 2017 May;21(4):967-973. [Medline: [27221516](#)] [doi: [10.1007/s00784-016-1858-4](#)]
29. De Cicco V, Cataldo E, Barresi M, Parisi V, Manzoni D. Sensorimotor trigeminal unbalance modulates pupil size. *Arch Ital Biol.* 2014 Mar;152(1):1-12. [Medline: [25181592](#)]
30. De Cicco V, Tramonti Fantozzi MP, Cataldo E, Barresi M, Bruschini L, Faraguna U, Manzoni D. Trigeminal, Visceral and Vestibular Inputs May Improve Cognitive Functions by Acting through the Locus Coeruleus and the Ascending Reticular Activating System: A New Hypothesis. *Front Neuroanat.* 2018 Jan 8;11:130. [Medline: [29358907](#)] [PMC free article: [5766640](#)] [doi: [10.3389/fnana.2017.00130](#)]
31. Ustabasioglu FE, Samanci C, Alis D, Samanci NS, Kula O, Olgun DC. Apparent Diffusion Coefficient Measurement in Mediastinal Lymphadenopathies: Differentiation between Benign and Malignant Lesions. *J Clin Imaging Sci.* 2017 Mar 6;7:12. [Medline: [28400998](#)] [PMC free article: [5360005](#)] [doi: [10.4103/2156-7514.201644](#)]
32. Mayil M, Keser G, Demir A, Pekiner FN. Assessment of Masseter Muscle Appearance and Thickness in Edentulous and Dentate Patients by Ultrasonography. *Open Dent J.* 2018 Sep 28;12:723-734. [Medline: [30369982](#)] [PMC free article: [6182884](#)] [doi: [10.2174/1745017901814010723](#)]
33. Smith PJ, Blumenthal JA, Hoffman BM, Cooper H, Strauman TA, Welsh-Bohmer K, Browndyke JN, Sherwood A. Aerobic exercise and neurocognitive performance: a meta-analytic review of randomized controlled trials. *Psychosom Med.* 2010 Apr;72(3):239-52. [Medline: [20223924](#)] [PMC free article: [2897704](#)] [doi: [10.1097/PSY.0b013e3181d14633](#)]
34. Chen H, Inuma M, Onozuka M, Kubo KY. Chewing Maintains Hippocampus-Dependent Cognitive Function. *Int J Med Sci.* 2015 Jun 9;12(6):502-9. [Medline: [26078711](#)] [PMC free article: [4466515](#)] [doi: [10.7150/ijms.11911](#)]
35. Wang R, Holsinger RMD. Exercise-induced brain-derived neurotrophic factor expression: Therapeutic implications for Alzheimer's dementia. *Ageing Res Rev.* 2018 Dec;48:109-121. [Medline: [30326283](#)] [doi: [10.1016/j.arr.2018.10.002](#)]
36. Jiang Z, Liu X, Lü Y. Unhealthy oral status contributes to the older patients with cognitive frailty: an analysis based on a 5-year database. *BMC Geriatr.* 2022 Dec 19;22(1):980. [Medline: [36536305](#)] [PMC free article: [9764571](#)] [doi: [10.1186/s12877-022-03673-5](#)]
37. Da D, Ge S, Zhang H, Zeng X, Jiang Y, Yu J, Wang H, Wu W, Xiao Z, Liang X, Zhao Q, Ding D, Zhang Y. Association between occlusal support and cognitive impairment in older Chinese adults: a community-based study. *Front Aging Neurosci.* 2023 Apr 17;15:1146335. [Medline: [37139086](#)] [PMC free article: [10149703](#)] [doi: [10.3389/fnagi.2023.1146335](#)]
38. Fontijn-Tekamp FA, Slagter AP, Van Der Bilt A, Van 'T Hof MA, Witter DJ, Kalk W, Jansen JA. Biting and chewing in overdentures, full dentures, and natural dentitions. *J Dent Res.* 2000 Jul;79(7):1519-24. [Medline: [11005738](#)] [doi: [10.1177/00220345000790071501](#)]
39. Lu Y, Pang Q, Wu Q, Luo B, Tang X, Jiang Q. Molar loss further exacerbates 2-VO-induced cognitive impairment associated with the activation of p38MAPK/NFκB pathway. *Front Aging Neurosci.* 2022 Nov 3;14:930016. [Medline: [36408103](#)] [PMC free article: [9669382](#)] [doi: [10.3389/fnagi.2022.930016](#)]
40. Khalaila R, Vitman-Schorr A, Cohn-Schwartz E. A prospective association between tooth status and cognitive performance among older adults in Europe. *Ageing Ment Health.* 2022 Mar;26(3):499-506. [Medline: [33635723](#)] [doi: [10.1080/13607863.2021.1891201](#)]
41. Budală DG, Balçoş C, Armencia A, Virvescu DI, Lupu CI, Baciu ER, Vasluianu RI, Tatarciuc M, Luchian I. Does the Loss of Teeth Have an Impact on Geriatric Patients' Cognitive Status? *J Clin Med.* 2023 Mar 16;12(6):2328. [Medline: [36983327](#)] [PMC free article: [10058759](#)] [doi: [10.3390/jcm12062328](#)]
42. Jun NR, Kim JH, Jang JH. Association of Denture Use and Chewing Ability with Cognitive Function Analysed Using Panel Data from Korea Longitudinal Study of Aging (2006-2018). *Healthcare (Basel).* 2023 Sep 10;11(18):2505. [Medline: [37761702](#)] [PMC free article: [10531446](#)] [doi: [10.3390/healthcare11182505](#)]
43. Kuoppala R, Näpänkangas R, Raustia A. Quality of Life of Patients Treated With Implant-Supported Mandibular Overdentures Evaluated With the Oral Health Impact Profile (OHIP-14): a Survey of 58 Patients. *J Oral Maxillofac Res.* 2013 Jul 1;4(2):e4. [Medline: [24422032](#)] [PMC free article: [3886109](#)] [doi: [10.5037/jomr.2013.4204](#)]
44. Yeung AWK, Leung WK. Functional Neuroplasticity of Adults with Partial or Complete Denture Rehabilitation with or without Implants: Evidence from fMRI Studies. *Nutrients.* 2023 Mar 24;15(7):1577. [Medline: [37049418](#)] [PMC free article: [10096841](#)] [doi: [10.3390/nu15071577](#)]

To cite this article:

Lopez-Chaichio L, Galindo-Moreno P, Padi-al-Molina M, Gutierrez-Garrido L, Rodriguez-Alvarez R, O'Valle F, Catena A. Mastication Influences Human Brain Anatomy

J Oral Maxillofac Res 2024;15(4):e4

URL: <http://www.ejomr.org/JOMR/archives/2024/4/e4/v15n4e4.pdf>

doi: [10.5037/jomr.2024.15404](https://doi.org/10.5037/jomr.2024.15404)

Copyright © Lopez-Chaichio L, Galindo-Moreno P, Padi-al-Molina M, Gutierrez-Garrido L, Rodriguez-Alvarez R, O'Valle F, Catena A. Published in the JOURNAL OF ORAL & MAXILLOFACIAL RESEARCH (<http://www.ejomr.org>), 31 December 2024.

This is an open-access article, first published in the JOURNAL OF ORAL & MAXILLOFACIAL RESEARCH, distributed under the terms of the [Creative Commons Attribution-Noncommercial-No Derivative Works 3.0 Unported License](https://creativecommons.org/licenses/by-nc-nd/3.0/), which permits unrestricted non-commercial use, distribution, and reproduction in any medium, provided the original work and is properly cited. The copyright, license information and link to the original publication on (<http://www.ejomr.org>) must be included.